Clinical Pharmacy Connect
ISSN: 3105-3874
2026, Article ID. 2026.0011, Cite as: https://doi.org/10.69709/CPC.2026.662244

SCIFINITI PUBLISHING

Case Report

OPEN ACCESS

Reversible Acute Kidney Injury Following Continuous Intravenous Diazepam in Generalized Tetanus: Recovery After Transition to Intravenous Midazolam: A Case Report

Waqar Ali[1,*], **Urooj Anwar**[2], **Jehan Zeb Khan**[3], **Irshad Khan**[4], **Iftikhar Ali**[5]

[1] Department of Clinical Pharmacy, Hayatabad Medical Complex, Peshawar 25100, Pakistan
[2] Department of Pharmacy, University of Peshawar, Peshawar 25100, Pakistan
[3] Department of Pharmacy, CECOS University, Peshawar 25100, Pakistan
[4] Surgical Unit A, Medical Teaching Institute-Hayatabad Medical Complex, Peshawar 25100, Pakistan
[5] College of Physical Medicine & Rehabilitation, Paraplegic Center, Hayatabad, Peshawar 25100, Pakistan

Article History
Received: April 29, 2026 Accepted: August 03, 2026 Published: September 06, 2026

Abstract
Background: Intravenous (IV) diazepam is formulated with propylene glycol (PG) as its solvent, and high-dose continuous infusions can lead to PG accumulation, hyperosmolality, anion gap metabolic acidosis, and acute kidney injury (AKI). Reports of this phenomenon specifically in tetanus patients treated with IV diazepam remain scarce. Propylene glycol toxicity is well recognized with intravenous lorazepam, yet PG-induced AKI following continuous intravenous diazepam infusion in generalized tetanus remains exceedingly rare in the literature; this case contributes a clearly documented instance with near-complete renal recovery after transition to midazolam. **Case Description:** A 21-year-old man with generalized tetanus received continuous IV diazepam (5–8 mL/h) in the ICU. By day 10, his peak blood urea reached 233 mg/dL and peak serum creatinine reached 6.55 mg/dL, indicating PG-induced AKI. Hemodialysis was performed on Days 7, 11, and 12, and diazepam was discontinued in favor of PG-free IV midazolam on Day 10. Renal parameters normalized progressively thereafter, and the patient was discharged in a clinically stable condition after 28 days. **Conclusion:** Prolonged, high-dose IV diazepam can cause clinically significant PG toxicity and AKI, making IV midazolam the preferred alternative for sustained ICU sedation in tetanus. Routine osmolar gap monitoring is essential whenever PG-containing infusions are used.

Keywords:
tetanus; diazepam; propylene glycol; acute kidney injury; midazolam; benzodiazepine toxicity; intensive care unit; case report

1. Introduction

Tetanus is a life-threatening infectious disease caused by tetanospasmin, the neurotoxin produced by Clostridium tetani. This exotoxin travels via retrograde axonal transport to inhibit the release of glycine and gamma-aminobutyric acid (GABA) at inhibitory synapses, producing uncontrolled muscle spasms, trismus, opisthotonus, and potentially fatal respiratory compromise [1]. Although nearly eliminated in high-income nations, tetanus still causes an estimated 30,000–50,000 deaths annually, the vast majority in low- and middle-income countries [2].

Standard management includes wound debridement, passive immunization with human tetanus immunoglobulin, metronidazole therapy, airway protection, and pharmacological control of spasms [3]. Benzodiazepines, which

* Corresponding Author:
Waqar Ali, Department of Clinical Pharmacy, Hayatabad Medical Complex, Peshawar 25100, Pakistan, aliwaqar241@gmail.com

© 2026 Copyright by the Authors.
Licensed as an open access article using a CC BY 4.0 license.

act on GABA-A receptors, remain the mainstay of spasm treatment, and IV diazepam is commonly favored, particularly in resource-poor settings, for its effectiveness and low cost. Severe generalized tetanus, however, may demand infusion doses well above the usual range [4].

In tetanus management, diazepam is typically initiated at 10–30 mg IV in adults and repeated every 1–4 h as needed. Prolonged or high-dose administration, however, can drive PG accumulation, producing hyperosmolarity and high-anion-gap metabolic (lactic) acidosis; these metabolic disturbances are frequently linked to acute kidney injury and may progress to multiorgan dysfunction. To mitigate this risk, continuous infusion of IV midazolam, a water-soluble benzodiazepine free of PG, is generally preferred whenever high-dose sedation is required [5–7]. Propylene glycol toxicity is well described with intravenous benzodiazepines, particularly lorazepam, and has also been reported with intravenous diazepam in critically ill patients [8]; nevertheless, reports of PG-induced acute kidney injury linked specifically to continuous intravenous diazepam infusion in generalized tetanus remain exceedingly rare. Here we describe a case of severe PG-induced acute kidney injury in a young tetanus patient receiving continuous IV diazepam, with near-complete renal recovery following transition to IV midazolam.

2. Case Presentation

A 21-year-old married male laborer with no known medical illness presented to the emergency department of a tertiary care hospital in Peshawar with a 10-day history of worsening trismus and inability to open his mouth, following an 11-day history of generalized body stiffness. His past medical history was notable only for neonatal seizures lasting approximately one week, which had resolved completely without recurrence or long-term sequelae. He had received no prior medical treatment or intervention for the current illness before admission, and there was no history of recent wound, trauma, or piercing. He could not provide details of his vaccination history, though childhood vaccination under the Expanded Programme on Immunization (EPI) was reported. On examination, blood pressure was 110/80 mmHg, pulse 55 beats/min, respiratory rate (RR) 18 breaths/min, temperature 98.0 °F, and oxygen saturation 95% on room air; generalized muscle stiffness with limited mouth opening was noted. Generalized tetanus was diagnosed on the basis of the clinical history together with the presence of trismus, risus sardonicus, generalized muscle rigidity, and painful reflex spasms, consistent with standard diagnostic criteria [9]. Cranial MRI revealed an incidental parieto-occipital arachnoid cyst, considered unrelated to the presenting symptoms. Initial blood tests showed mild leukocytosis (WBC 13.5 × 103/μL), hemoglobin 12.8 g/dL, platelets 283 × 103/μL, and a mildly elevated alanine aminotransferase (ALT 78 U/L); renal function was preserved at baseline, with urea 66 mg/dL and creatinine 0.65 mg/dL. Creatine kinase (CK) was markedly elevated (3829 U/L), consistent with vigorous, prolonged muscular activity, while random blood glucose was 86 mg/dL and hepatitis C serology was negative.

On Day 1, the patient received tetanus antitoxin (Tetagam® 3000 IU, IM), IV antibiotics (metronidazole and amoxicillin-clavulanate), and IV diazepam to control spasms. By Day 2, increasing spasm frequency and declining oxygen saturation necessitated ICU admission; he was orotracheally intubated and started on volume-controlled ventilation, and the diazepam infusion was increased to 8 mL/h (16 mg/h), using diazepam injection (commercial concentration 5 mg/mL) diluted to a final concentration of 2 mg/mL. The tetanus antitoxin dose was increased to 5000 IU, and atracurium was started to induce neuromuscular paralysis. From Day 3 onward, renal function monitoring revealed a progressive rise in serum creatinine (from 0.65 to 6.55 mg/dL) and blood urea (from 66 to 233 mg/dL), accompanied by a calculated osmolar gap of approximately 20–50 mOsm/kg during Days 3–10, findings consistent with PG-induced AKI, as illustrated in Figure 1. No other nephrotoxic exposure or history of renal disease was identified. Causality was assessed using the Naranjo Adverse Drug Reaction Probability Scale, yielding a total score of 5, consistent with a probable adverse drug reaction; this score reflected previous conclusive reports (+1), onset of the reaction after diazepam administration (+2), improvement following diazepam withdrawal (+1), and objective laboratory evidence confirming the reaction (+1) [10]. The patient underwent hemodialysis on Days 7 (ultrafiltration [UF] 200 mL), 11 (UF 1.5 L), and 12 (UF 1.5 L) to clear PG and its metabolites. IV diazepam was discontinued on Day 10 and replaced with IV midazolam, and IV magnesium sulfate (6 g, 48 mEq, diluted in 500 mL normal saline) was administered over 3 h to help control spasms and autonomic instability. Following the transition to midazolam, renal function improved steadily: creatinine fell from 6.55 mg/dL (Day 10) to 3.8 mg/dL (Day 20) and to approximately 0.95 mg/dL by discharge (Day 28), with blood urea declining in parallel. Spasms improved markedly, allowing extubation, and the patient received a booster dose of tetanus toxoid (0.5 mL IM) before discharge. He completed a 28-day ICU stay and was discharged in good condition, having given consent for publication. The full clinical and laboratory course is summarized in Tables 1 and 2.

2026, Vol. 2, Article ID. 2026.0011
https://doi.org/10.69709/CPC.2026.662244

Table 1: Chronological clinical timeline of the ICU admission.

Day(s)	Clinical Events	Key Investigations	Medications/Interventions
Day 1	Admission; trismus, generalized spasm; O_2 sat 95%; BP 110/80; oriented, afebrile. Transferred to the medical ward.	WBC 13.5 × 10^3/μL; Hb 12.8 g/dL; Creatinine 0.65 mg/dL; Urea 66 mg/dL; CK 3829 U/L; ALT 78 U/L; HCV (hepatitis C virus): negative; brain MRI: incidental cyst	Tetagam® 3000 IU IM; Metronidazole IV; Amoxicillin-clavulanate IV; IV Diazepam commenced
Day 2	Worsening spasms; declining O_2 sat. ICU transfer; intubated; mechanical ventilation commenced.	BP 112/65; PR 51; RR 25; CXR (chest X-ray)/ABG (arterial blood gas) requested	Tetagam® 5000 IU; IV Diazepam 8 mL/h (16 mg/h); IV Atracurium; IV Metronidazole
Days 3–6	Ongoing sedation and neuromuscular blockade; spasm partially controlled; ventilator-dependent.	Creatinine rising progressively; peak reached on Day 10; urea rising to 233 mg/dL; osmolar gap elevated	IV Diazepam 5–8 mL/h continuously; IV Atracurium; supportive infusions
Day 7	AKI confirmed; first hemodialysis (UF 200 mL); hemodynamics stabilized.	Creatinine 5.72 mg/dL; Urea 225 mg/dL; osmolar gap elevated	Hemodialysis; continued IV Diazepam; supportive care
Days 8–10	Spasms persisting; ventilator-dependent; decision to switch to IV Midazolam.	Creatinine peaked ≈6.55 mg/dL; serial monitoring	IV Diazepam discontinued (Day 10); IV Midazolam commenced; Magnesium sulfate added
Days 11–12	Hemodialysis repeated (Day 11: UF 1.5 L; Day 12: UF 1.5 L); renal parameters beginning to trend downward.	Creatinine and urea declining	IV Midazolam; hemodialysis ×2; supportive therapy
Days 13–20	Gradual ventilator weaning; spasms significantly reduced.	Creatinine 3.8 mg/dL by Day 20	IV Midazolam; IV Magnesium sulphate; Tetanus toxoid 0.5 mL IM (booster)
Days 21–28	Weaned from ventilation; asymptomatic, afebrile. Discharged in stable condition	Creatinine ≈ 0.95 mg/dL; Urea 55 mg/dL	Oral medications; rehabilitation; discharge after 28-day ICU stay

AKI: acute kidney injury; BP: blood pressure; CK: creatine kinase; CXR: chest X-ray; HCV: hepatitis C virus; ICU: intensive care unit; IM: intramuscular; IV: intravenous; MRI: magnetic resonance imaging; UF: ultrafiltration.

Table 2: Serial laboratory parameters from admission to discharge.

Parameter	Admission (Day 1)	Peak Value (Day 10)	Midazolam Switch (Day 20)	Discharge (Day 28)
Serum Creatinine (mg/dL)	0.65	6.55	3.8	0.95
Blood Urea (mg/dL)	66	233	-	55
WBC (×10^3/μL)	13.5	—	—	Within normal limits
Hemoglobin (g/dL)	12.8	—	—	Stable
CK (U/L)	3829 (elevated)	—	—	Declining
ALT (U/L)	78	—	—	Improved
O_2 Saturation (%)	95	—	98	98
Blood Pressure (mmHg)	110/80	—	119/88	Normal

AKI was defined as a creatinine rise exceeding 1.5× baseline within 7 days, per KDIGO (kidney disease: Improving Global Outcomes) criteria. Normal reference ranges were serum creatinine 0.64–1.2 mg/dL and blood urea 10–50 mg/dL.

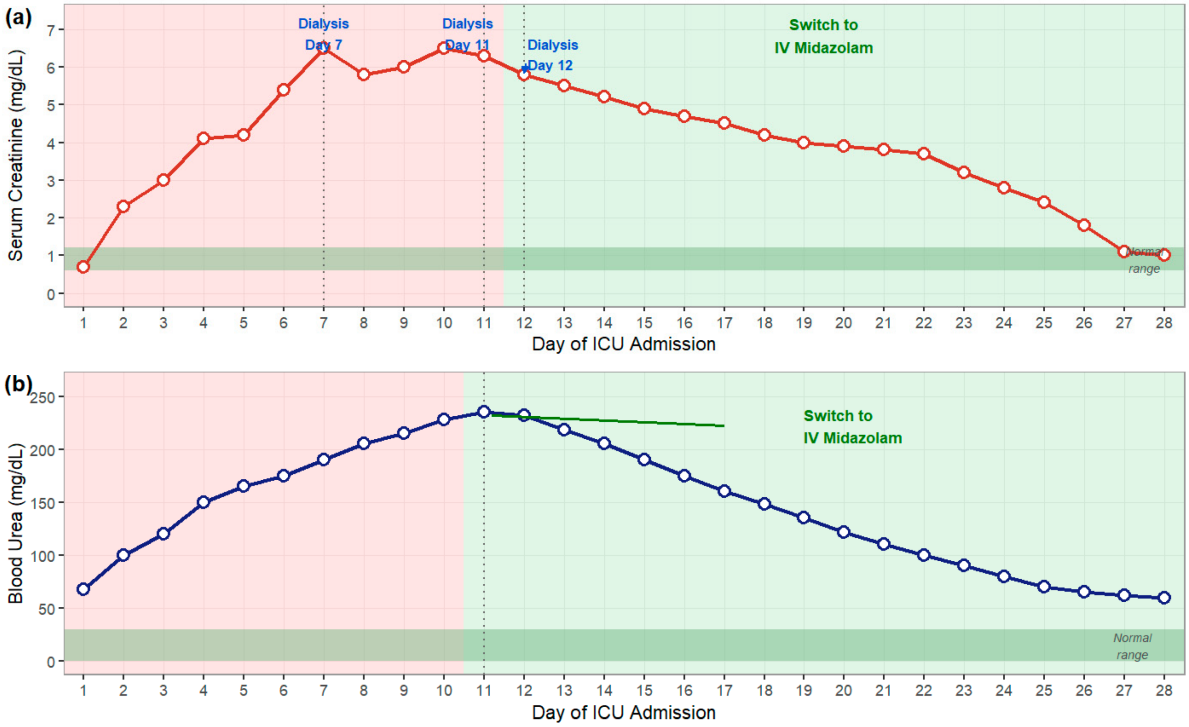

Figure 1: Serum creatinine (**a**) and blood urea (**b**) trends during hospitalization, showing the rise associated with IV diazepam and the subsequent recovery after switching to IV midazolam.

3. Discussion

We report a life-threatening case of PG-induced AKI following high-dose, continuous IV diazepam in a patient with generalized tetanus. Several features together point to PG as the likely cause: the temporal correlation between the rise in creatinine and urea and the ongoing infusion of PG-containing diazepam, the elevated osmolar gap, the improvement seen with hemodialysis, and the rapid resolution of renal failure after substitution with midazolam. The patient also received atracurium, metronidazole, amoxicillin-clavulanate, and magnesium sulfate, none of which are established causes of acute kidney injury under routine therapeutic use; although rare cases of nephrotoxicity have been reported with metronidazole and amoxicillin-clavulanate, the clinical course and temporal association in this patient favored propylene glycol toxicity as the more likely explanation. Alternative causes of AKI were carefully weighed and excluded. Rhabdomyolysis was considered unlikely, since the creatine kinase elevation (3829 U/L) fell well below the levels typically associated with rhabdomyolysis-induced AKI, and there was no clinical evidence of myoglobinuria. Sepsis-associated AKI and hemodynamic or volume-related renal injury were similarly judged unlikely, as the patient remained hemodynamically stable with no features suggestive of significant sepsis or hypovolemia, and contrast-induced nephropathy was excluded outright, since no contrast-enhanced imaging was performed during hospitalization. While propylene glycol-induced toxicity associated with intravenous diazepam has been reported in critically ill patients, published reports of PG-induced acute kidney injury during continuous intravenous diazepam infusion specifically in generalized tetanus remain very limited.

PG toxicity is most thoroughly characterized in the context of IV lorazepam, which also contains PG. Yahwak et al. established the osmolar gap as a practical surrogate marker for PG accumulation in critically ill adults receiving prolonged lorazepam infusions [11].

Similarly, at infusion rates of 8 mL/h, as in the present case, daily PG delivery from IV diazepam has also been associated with nephrotoxicity. An osmolar gap exceeding 10 mOsm/kg should prompt consideration of PG toxicity in patients receiving such infusions [12]. Serum PG concentrations, while confirmatory, are not routinely available in resource-limited settings, making the osmolar gap the most practical bedside monitoring tool.

A critical and often underappreciated feature of PG toxicity is its clinical mimicry of sepsis. Rising creatinine and urea, hemodynamic instability, and metabolic acidosis in an ICU patient are frequently attributed to infection or disease progression rather than to the infusion it-

2026, Vol. 2, Article ID. 2026.0011
https://doi.org/10.69709/CPC.2026.662244

self. Clinicians should therefore maintain a high index of suspicion for iatrogenic PG toxicity whenever these findings coincide temporally with prolonged PG-containing infusions in the absence of microbiological evidence. Because IV midazolam contains no PG, it eliminates this specific toxicity pathway altogether. Early reports demonstrated effective sedation with prolonged IV midazolam in tetanus patients, and subsequent evidence has continued to support its safety and efficacy in this indication [12,13].

Autonomic dysfunction, a recognized complication of severe generalized tetanus that portends a poor prognosis [14], was managed in this case with adjunctive IV magnesium sulfate. A landmark randomized controlled trial by Thwaites et al. [15] demonstrated that magnesium reduces spasms and autonomic instability compared with placebo, supporting its role as a complementary agent; the comparative pharmacological properties of IV diazepam and IV midazolam relevant to tetanus management are summarized in Table 3. The clinical pharmacist played an important role in the multidisciplinary management of this patient, first by recognizing the potential link between prolonged high-dose intravenous diazepam therapy and the otherwise unexplained development of acute kidney injury, and identifying cumulative propylene glycol exposure from the diazepam formulation as a likely contributing factor based on the patient's clinical course. The pharmacist further supported ongoing therapeutic monitoring by reviewing renal function trends and laboratory parameters after the medication change, and worked with the intensive care team to optimize benzodiazepine dosing and sedation strategy in order to reduce the risk of propylene glycol toxicity in similarly high-risk patients.

Table 3: Comparative properties of IV diazepam and IV midazolam relevant to tetanus management in the *ICU*.

Feature	IV Diazepam	IV Midazolam
Vehicle/Solvent	Propylene glycol (PG)	None (water-soluble)
Risk of PG toxicity	High at prolonged/high doses	Absent
AKI/osmolar gap risk	Yes documented in this case	Minimal
Duration of action	Long-acting	Short-acting (titratable)
ICU sedation suitability	Limited by PG accumulation	Preferred for prolonged sedation
Cost	Lower	Relatively higher
Evidence in tetanus	Established; PG risk	Growing; recommended for prolonged use

ICU: intensive care unit; PG: propylene glycol; AKI: acute kidney injury.

This case report has the inherent limitations of a single-case study. Serum propylene glycol concentrations and arterial blood gas analysis were not available at our center, so the diagnosis of propylene glycol-induced acute kidney injury rested on the temporal relationship between prolonged intravenous diazepam exposure and renal dysfunction rather than on direct biochemical confirmation. Future studies should incorporate routine osmolar gap monitoring and, where feasible, direct serum propylene glycol measurement to strengthen the diagnosis of PG toxicity in patients receiving prolonged propylene glycol-containing infusions.

4. Conclusions

Continuous high-dose IV diazepam, a widely used agent for tetanus spasm control, can cause severe, potentially reversible AKI mediated by its solvent vehicle, propylene glycol; early recognition, supported by routine osmolar gap monitoring, is therefore essential. When sustained high-dose benzodiazepine therapy is required in the ICU, IV midazolam should be considered as an alternative, since its PG-free formulation avoids this specific toxicity risk entirely. In this patient, switching to IV midazolam, supported by hemodialysis and adjunctive magnesium sulfate, enabled full clinical recovery. Clinicians practicing in settings where IV diazepam is routinely used for tetanus should remain aware of this iatrogenic risk and implement appropriate monitoring protocols.

List of Abbreviations

ABG	Arterial Blood Gas
AKI	Acute Kidney Injury
ALT	Alanine Aminotransferase
BP	Blood Pressure
CK	Creatine Kinase
CXR	Chest X-Ray
EPI	Expanded Programme on Immunization
GABA	Gamma-Aminobutyric Acid

HCV	Hepatitis C Virus
ICU	Intensive Care Unit
IM	Intramuscular
IV	Intravenous
KDIGO	Kidney Disease Improving Global Outcomes
MRI	Magnetic Resonance Imaging
PG	Propylene Glycol
PR	Pulse Rate
RR	Respiratory Rate
UF	Ultrafiltration
WBC	White Blood Cell Count

Author Contributions

Conceptualization: I.A. and W.A.; Investigation: U.A. and J.Z.K.; Data curation: W.A., U.A., and I.K.; Visualization: W.A. and I.K.; Writing—original draft preparation: W.A., U.A., and I.K.; Writing—review & editing: I.A. and I.K.; Supervision: I.A.; Resources: I.A.; Project administration: I.A. All authors have read and agreed to the published version of the manuscript.

Availability of Data and Materials

The data supporting the findings of this case report consist of de-identified clinical and laboratory information drawn from the patient's medical records. All relevant data are included within this manuscript, and no additional datasets were generated beyond those reported here.

Ethics Committee Approval and Consent to Participate

This report describes a single clinical case arising from routine clinical care and does not involve an experimental intervention or prospective research protocol. Therefore, formal Institutional Review Board (IRB) or Ethics Committee approval was not obtained for this case report. The report was prepared in accordance with applicable ethical principles for the protection of patient privacy and confidentiality.

Human Rights Statement

The authors confirm that this case report was prepared in accordance with the ethical principles of the Declaration of Helsinki (1964) and its subsequent amendments. Patient privacy and confidentiality were maintained throughout the preparation and reporting of this case.

Consent for Publication

The patient provided written informed consent for publication of this case report, along with all accompanying figures and clinical data.

Conflicts of Interest

The authors declare no conflicts of interest.

Funding

The study did not receive any external funding and was conducted using only institutional resources.

Acknowledgments

The authors extend sincere appreciation to the nursing and paramedical staff of the ICU at Hayatabad Medical Complex, Peshawar, for their dedicated care of the patient, and to the patient and his family for their cooperation and written consent for publication.

AI Declaration

The authors acknowledge the use of an AI-based tool during the preparation of this manuscript. Specifically, ChatGPT (OpenAI) was used for language editing, grammar refinement, and improvement of sentence structure to enhance clarity and readability.

Standard Reporting Guidelines

This case report was prepared in substantial compliance with the CARE (Case Report) 2013 guidelines for reporting individual cases in clinical medicine. It addresses all applicable CARE reporting domains, including title, keywords, abstract, introduction, patient information, clinical findings, timeline, diagnostic assessment, therapeutic interventions, follow-up and outcomes, discussion, and informed consent. A first-person patient perspective could not be obtained, as the patient was lost to follow-up after hospital discharge; consequently, his views on the illness, treatment, and recovery could not be formally documented.

Supplementary Materials

Supplementary material associated with this article has been published online and is available at: https://www.scifiniti.com/3105-3874/2/2026.0011.

References

[1] Karna, P.; Thakur, A.K. Tetanus—A Lethal and Neglected Infectious Disease. *Ann. Med. Surg.* **2025**, *87*, 4567–4569. [CrossRef]

[2] GBD 2021 Nervous System Disorders Collaborators. Global, Regional, and National Burden of Disorders Affecting the Nervous System, 1990–2021: A Systematic Analysis for the Global Burden of Disease Study 2021. *Lancet Neurol.* **2024**, *23*, 344–381. [CrossRef] [PubMed]

[3] Rodrigo, C.; Fernando, D.; Rajapakse, S. Pharmacological Management of Tetanus: An Evidence-Based Review. *Crit. Care* **2014**, *18*, 217. [CrossRef]

[4] Karnad, D.R.; Gupta, V. Intensive Care Management of Severe Tetanus. *Indian J. Crit. Care Med.* **2021**, *25*, S155–S160. [CrossRef]

[5] Pfizer Inc. Diazepam Injection, USP: Prescribing Information 2023. Available online: https://labeling.pfizer.com/ShowLabeling.aspx?id=4460 (accessed on 7 July 2026).

[6] Kumar, A.; Kumar, S.; Kadam, L.; Singh, R.; Yadav, R.P. Intravenous Diazepam Infusion in Tetanus: An Experience in Balancing a Unique Clinical Challenge. *Indian J. Crit. Care Case Rep.* **2025**, *4*, 101–103. [CrossRef]

[7] Chouksey, S.S.; Jain, A.; Chaurasia, R.N.; Singh, V.K. Generalised Tetanus Managed with Continuous Diazepam Infusion in a Resource-Constrained Setting: A Case Report. *J. Rare Dis.* **2025**, *4*, 64. [CrossRef]

[8] Wilson, K.C.; Reardon, C.; Theodore, A.C.; Farber, H.W. Propylene Glycol Toxicity: A Severe Iatrogenic Illness in ICU Patients Receiving IV Benzodiazepines: A Case Series and Prospective, Observational Pilot Study. *Chest* **2005**, *128*, 1674–1681. [CrossRef]

[9] Sudarshan, R.; Sayo, A.R.; Renner, D.R.; de Saram, S.; Godbole, G.; Warrell, C.; Duong, H.T.H.; Thwaites, C.L.; Mehta, A.R.; Coughlan, C. Tetanus: Recognition and Management. *Lancet Infect. Dis.* **2025**, *25*, e645–e657. [CrossRef]

[10] Naranjo, C.A.; Busto, U.; Sellers, E.M.; Sandor, P.; Ruiz, I.; Roberts, E.A.; Janecek, E.; Domecq, C.; Greenblatt, D.J. A Method for Estimating the Probability of Adverse Drug Reactions. *Clin. Pharmacol. Ther.* **1981**, *30*, 239–245. [CrossRef]

[11] Yahwak, J.A.; Riker, R.R.; Fraser, G.L.; Subak-Sharpe, S. Determination of a Lorazepam Dose Threshold for Using the Osmol Gap to Monitor for Propylene Glycol Toxicity. *Pharmacotherapy* **2008**, *28*, 984–991. [CrossRef]

[12] Gyasi, H.K.; Fahr, J.; Kurian, E.; Mathew, M. Midazolam for Prolonged Intravenous Sedation in Patients with Tetanus. *Middle East J. Anaesthesiol.* **1993**, *12*, 135–141. [PubMed]

[13] Lim, T.Y.; Poole, R.L.; Pageler, N.M. Propylene Glycol Toxicity in Children. *J. Pediatr. Pharmacol. Ther.* **2014**, *19*, 277–282. [CrossRef]

[14] Wasay, M.; Khealani, B.A.; Talati, N.; Shamsi, R.; Syed, N.A.; Salahuddin, N. Autonomic Nervous System Dysfunction Predicts Poor Prognosis in Patients with Mild to Moderate Tetanus. *BMC Neurol.* **2005**, *5*, 2. [CrossRef]

[15] Thwaites, C.L.; Yen, L.M.; Loan, H.T.; Thuy, T.T.D.; Thwaites, G.E.; Stepniewska, K.; Soni, N.; White, N.; Farrar, J. Magnesium Sulphate for Treatment of Severe Tetanus: A Randomised Controlled Trial. *Lancet* **2006**, *368*, 1436–1443. [CrossRef]

Disclaimer/Publisher's Note: The views expressed in this article are those of the author(s) and do not necessarily reflect the views of the publisher or editors. The publisher and editors assume no responsibility for any injury or damage resulting from the use of information contained herein.