Disclaimer: This is not the final version of the article. Changes may occur when the manuscript is published in its final format.

Extensive Bilateral Optic Pathway Glioma Presenting with Chorea and Neuroregression in a Child: A Case Report

Naman Maheshwari — Senior Resident, Department of Diagnostic and Interventional Radiology, All India Institute of Medical Sciences (AIIMS), Rishikesh, Uttarakhand, India. Email: naman0396@gmail.com; ORCID: https://orcid.org/0009-0006-3236-0125

Archit Gupta — Junior Resident, Department of Diagnostic and Interventional Radiology, All India Institute of Medical Sciences (AIIMS), Rishikesh, Uttarakhand, India. Email: architg.aiimsdelhi@gmail.com; ORCID: https://orcid.org/0009-0005-3861-6147

Kartik Singh — Junior Resident, Department of Diagnostic and Interventional Radiology, All India Institute of Medical Sciences (AIIMS), Rishikesh, Uttarakhand, India. Email: kartiksinghfcb10@gmail.com; ORCID: https://orcid.org/0009-0008-5525-8611

Naman Gupta (Corresponding Author) — Senior Resident, Department of Diagnostic and Interventional Radiology, All India Institute of Medical Sciences (AIIMS), Rishikesh, Uttarakhand, India. Email: namangupta0391@gmail.com; ORCID: https://orcid.org/0009-0000-4198-4892

Pankaj Sharma — Additional Professor, Department of Diagnostic and Interventional Radiology, All India Institute of Medical Sciences (AIIMS), Rishikesh, Uttarakhand, India. Email: pankajrad7477@yahoo.com; ORCID: https://orcid.org/0000-0003-4088-1554

Abstract

Background: Optic pathway glioma is the most common tumour of the visual pathway in children and typically presents with visual disturbance, proptosis, or, in infants, diencephalic syndrome. Extension beyond the optic nerves and chiasm into the hypothalamus, thalami, and brainstem is uncommon and can produce non-visual neurological presentations that are easily mistaken for other encephalopathic processes.

Case presentation: A 10-year-old boy was referred for contrast-enhanced magnetic resonance imaging (MRI) of the brain and orbits after presenting with a febrile illness accompanied by childhood-onset neuroregression, visual impairment, and multiple episodes of chorea. Imaging showed diffuse, fusiform, non-enhancing enlargement of both optic nerves, the chiasm, and both optic tracts, without diffusion restriction, extending contiguously into the hypothalamus, both thalami, midbrain, and pons. Thalamic enlargement effaced the third ventricle and produced obstructive hydrocephalus with periventricular ooze (Evans index 0.54); an incidental empty sella was noted. This pattern corresponded to modified Dodge/Taylor stage 4 optic pathway glioma, and clinical correlation for neurofibromatosis type 1 was recommended.

Conclusion: This case shows that extensive bilateral optic pathway glioma with posterior diencephalic and brainstem extension can present with predominantly non-visual neurological features — neuroregression and chorea — rather than the isolated visual symptoms typically emphasised in the literature, and can be complicated by obstructive hydrocephalus requiring urgent recognition. Recognising the characteristic bilateral, fusiform, non-enhancing optic-pathway signal abnormality on MRI is key to distinguishing this tumour from inflammatory, infectious, and

infiltrative mimics, guiding prompt multidisciplinary management, and directing appropriate evaluation for neurofibromatosis type 1.

Keywords: optic pathway glioma; neurofibromatosis type 1; hydrocephalus; chorea; modified dodge/taylor classification; paediatric neuro-oncology; magnetic resonance imaging.

Highlights

- Extensive bilateral optic pathway glioma extended into the thalami and brainstem.
- The tumour presented atypically: neuroregression and chorea, with visual impairment.
- Bilateral, fusiform, non-enhancing MRI signal was the key diagnostic clue.
- Thalamic mass effect caused obstructive hydrocephalus needing urgent care.
- Café-au-lait macules, axillary freckling, and OPG warrant formal NF1 evaluation.

1. Introduction

Optic pathway glioma (OPG) accounts for 3–5% of intracranial tumours in children and is the most common neoplasm of the visual pathway in this age group *[1,2]*. Most are World Health Organization (WHO) grade 1 pilocytic astrocytomas driven by mitogen-activated protein kinase (MAPK) pathway alterations, most commonly a *KIAA1549–BRAF* fusion in sporadic disease *[2,3]*. Approximately 15–20% of children with neurofibromatosis type 1 (NF1) develop an OPG, and OPG is itself one of the diagnostic criteria for NF1 *[1,4]*.

Anatomically, OPG may involve any segment of the visual pathway from the optic nerve to the optic radiations, with or without extension into the adjacent hypothalamus. Since 1958, the Dodge classification has staged these tumours by anatomical extent, and a modified, MRI-based system

proposed by Taylor et al. refined this staging to capture the more detailed anatomical information available on modern imaging, separately documenting involvement of the nerve, chiasm, hypothalamus, and other posterior structures *[5]*. Tumours confined to the optic nerve(s) typically present with proptosis, nystagmus, or asymmetric visual loss, whereas chiasmatic and post-chiasmatic (hypothalamic or more posterior) extension is associated with a higher likelihood of visual field deficit, endocrinopathy, diencephalic syndrome in infants, obstructive hydrocephalus, and a generally more guarded functional prognosis *[5,6]*.

Extension of OPG into the thalami, midbrain, and pons, as seen in the present case, is distinctly uncommon and is not well represented in the case-report literature, which more typically describes isolated nerve, chiasmatic, or hypothalamic disease *[7,8]*. Because such extensive posterior involvement can disrupt thalamocortical and subcortical circuitry, it may manifest with neurological features outside the classical visual triad, including movement disorders and encephalopathy-like regression, which can mimic infectious or autoimmune aetiologies and delay recognition of the underlying tumour.

We report a child with extensive bilateral OPG involving the optic nerves, chiasm, tracts, hypothalamus, thalami, midbrain, and pons — corresponding to modified Dodge/Taylor stage 4 disease — who presented with febrile neuroregression and chorea rather than isolated visual symptoms, and who developed obstructive hydrocephalus from thalamic mass effect on the third ventricle. This report describes the imaging features that established the diagnosis, reviews the modified Dodge/Taylor staging system and its clinical correlates, and discusses the differential diagnosis and contemporary, evidence-based management of advanced OPG, including the expanding role of MEK- and RAF-directed targeted therapy.

2. Materials and Methods

This report describes the clinical history, examination findings, and diagnostic imaging of a single paediatric patient, derived from the medical record and from a contrast-enhanced magnetic resonance imaging examination of the brain and orbits performed as part of routine diagnostic care at the All India Institute of Medical Sciences (AIIMS), Rishikesh; the imaging acquisition protocol is detailed in Section 3.2 (Imaging Findings). The manuscript was prepared and is reported in accordance with the CARE (CAse REport) guidelines, as detailed in the Standards of Reporting section.

Use of Artificial Intelligence in Manuscript Preparation

In accordance with the journal's policy on artificial intelligence and the Committee on Publication Ethics (COPE) position statement on AI tools in scholarly publishing, the authors disclose the following. A generative AI large language model, ChatGPT (OpenAI), was used solely as a writing-assistance tool during the drafting of this manuscript, restricted to grammar correction, language refinement, and improving the clarity, flow, and readability of sentences already drafted by the human authors. All clinical data, imaging interpretation, literature review, and scientific conclusions in this manuscript originate from, were verified by, and are the full responsibility of the named human authors, who reviewed every AI-assisted language edit for factual and scientific accuracy before submission. The tool is named and formally acknowledged in the AI-declaration section.

3. Case Presentation

3.1 Clinical History and Examination

A 10-year-old boy was referred from the paediatrics department for contrast-enhanced MRI of the brain and orbits (3 T). The clinical information provided at the time of the scan was of a febrile illness with childhood-onset neuroregression, visual impairment, and multiple episodes of chorea.

There was no significant past medical history and no prior medical evaluation for these symptoms. This acute febrile episode was the family's first presentation to medical care for the neuroregression, visual impairment, and chorea; the exact duration of the antecedent neuroregression and visual symptoms prior to this presentation could not be ascertained from the available history, and there was no prior medical or surgical intervention related to the present illness. The patient was the only child in the family, and there was no significant family history, including no known family history of neurofibromatosis type 1 or other inherited neurological or oncological disorders. The clinical course is summarised chronologically in **Table 1**.

Table 1. Clinical timeline, presented as relative chronology since exact dates are not reported for patient confidentiality.

Phase	Clinical course
Background	Childhood-onset neuroregression and visual impairment, of undocumented prior duration
Presenting episode	Acute febrile illness with multiple episodes of chorea, prompting medical attention
Clinical evaluation	Paediatric assessment; laboratory work-up (haematological, inflammatory, metabolic, endocrine, cerebrospinal fluid, infectious, and autoimmune screening) — unremarkable
Diagnostic imaging	Contrast-enhanced MRI of the brain and orbits performed
Diagnosis	Extensive bilateral optic pathway glioma, modified Dodge/Taylor stage 4, identified
Planned management	Multidisciplinary referral recommended (paediatric neurosurgery, neuro-oncology, ophthalmology, endocrinology); clinical/genetic correlation for NF1 recommended

Examination

On general examination, the child was haemodynamically stable with normal anthropometric parameters and was afebrile at examination. Dermatological examination revealed multiple café-au-lait macules and axillary freckling, while no cutaneous or plexiform neurofibromas or other skeletal stigmata of NF1 were identified. Ophthalmological evaluation revealed bilateral blurring of vision without ophthalmoplegia. Neurological examination demonstrated neuroregression with recurrent choreiform movements; no other focal neurological deficits were documented. Routine laboratory investigations, including complete blood count, inflammatory markers, metabolic and endocrine evaluation, cerebrospinal fluid (CSF) analysis, and clinically indicated infectious and autoimmune work-up, were unremarkable. NF1 genetic testing had not been performed at the time of reporting and was planned as part of the subsequent evaluation.

3.2 Imaging Findings

Technique

Multiplanar images of the brain were acquired using T1-weighted (T1W), T2-weighted (T2W), T2 fluid-attenuated inversion recovery (FLAIR), diffusion-weighted (DWI), and susceptibility-weighted (SWI) sequences. FLAIR and fat-saturated T1W images were repeated after intravenous administration of a gadolinium-based contrast agent. Multiplanar images of the orbits were acquired using T1W, T2W, T2 FLAIR, and short-tau inversion recovery (STIR) sequences.

Findings

Diffuse fusiform enlargement with altered signal intensity was seen involving both optic nerves along their intraorbital, intracanalicular, and intracranial segments, isointense to grey matter on T1W images and mildly hyperintense on T2W/FLAIR images, without diffusion restriction,

susceptibility blooming, or post-contrast enhancement. The abnormality extended posteriorly to involve the optic chiasm and both optic tracts. Both optic nerve sheath complexes were distended with flattening of the posterior sclera, and both optic nerves were tortuous; maximum calibre measured approximately 11.4 mm on the right and 9.3 mm on the left. The extraocular muscles were symmetrical without focal abnormality, and both globes were unremarkable (Figure 1).

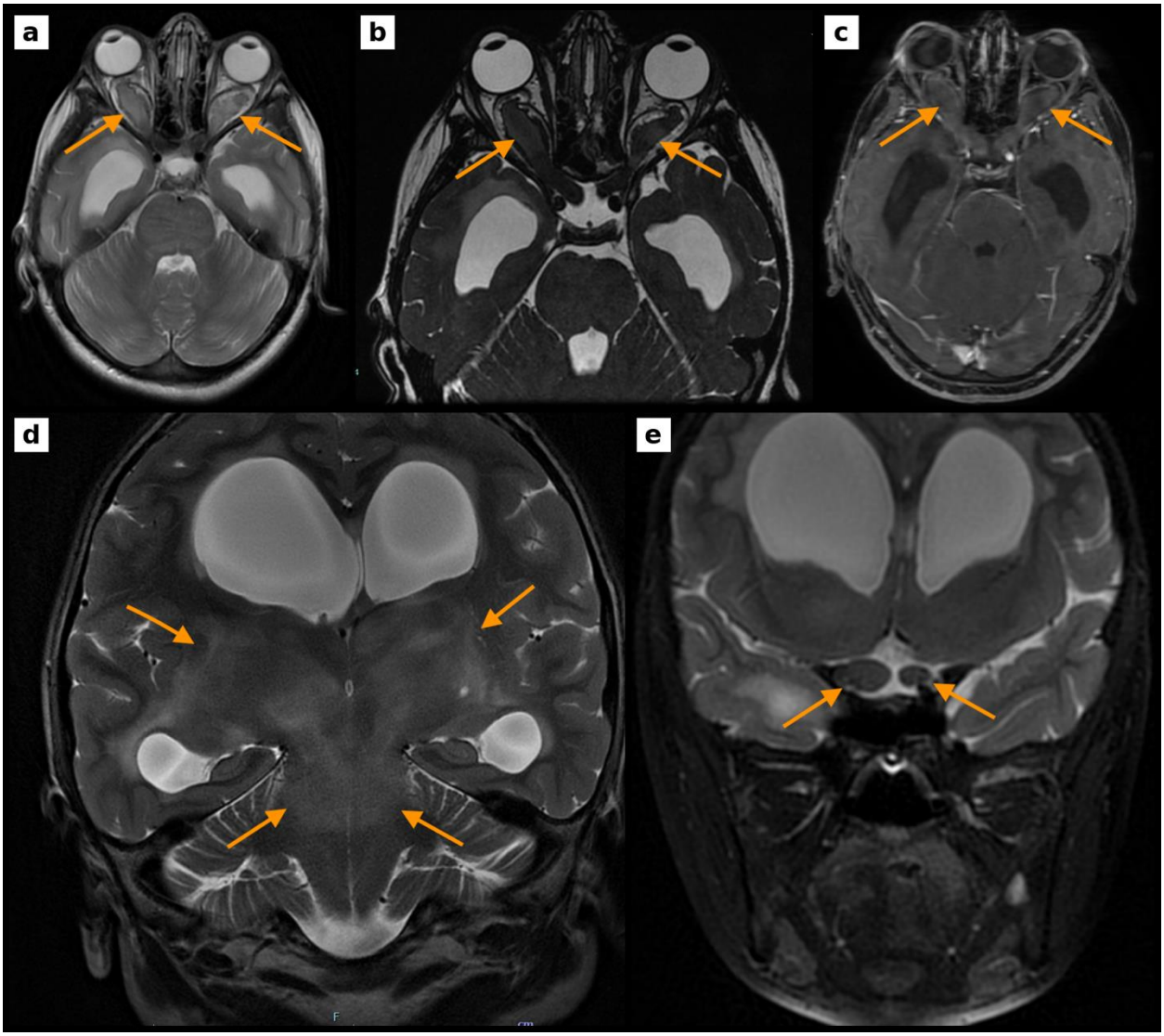

Figure 1. Contrast-enhanced MRI of the orbits and skull base demonstrates diffuse, fusiform enlargement of both optic nerves and the optic chiasm. (a) Axial T2-weighted and (b) axial 3D FIESTA images at the level of the orbits and suprasellar cistern show symmetric, tortuous thickening of both optic nerves (yellow arrows) and the chiasm,

with mild T2 hyperintensity extending into the perimesencephalic cistern. (c) Axial fat-saturated post-contrast T1-weighted image at the same level shows no abnormal enhancement of the enlarged nerves (yellow arrows) or chiasm. (d) Coronal T2-weighted image demonstrates bulky mildly T2-hyperintense enlargement of the bilateral thalami with extension into the midbrain and upper pons (yellow arrows), associated with dilatation of the lateral ventricles. (e) Coronal T2-weighted images through the orbits, at two levels, show symmetric bilateral optic nerve enlargement (yellow arrows) with distended nerve sheath complexes and preserved, symmetrical extraocular muscles.

Ill-defined mild T2/FLAIR hyperintensity with diffuse bulky expansion was present in both thalami, the hypothalamic/chiasmatic region, the midbrain, and the pons, again without diffusion restriction, susceptibility blooming, or significant post-contrast enhancement, and without cystic change, necrosis, or haemorrhage.

The bilateral thalamic enlargement produced significant mass effect on the third ventricle, which was nearly completely effaced, with resultant upstream obstructive hydrocephalus. Both lateral ventricles were prominently dilated with periventricular T2/FLAIR hyperintensity consistent with periventricular ooze. The Evans index measured approximately 0.54; maximum frontal horn width measured approximately 36.6 mm on the right and 28.7 mm on the left. The fourth ventricle was normal in calibre (approximately 14.2 × 16.4 mm) (Figure 2).

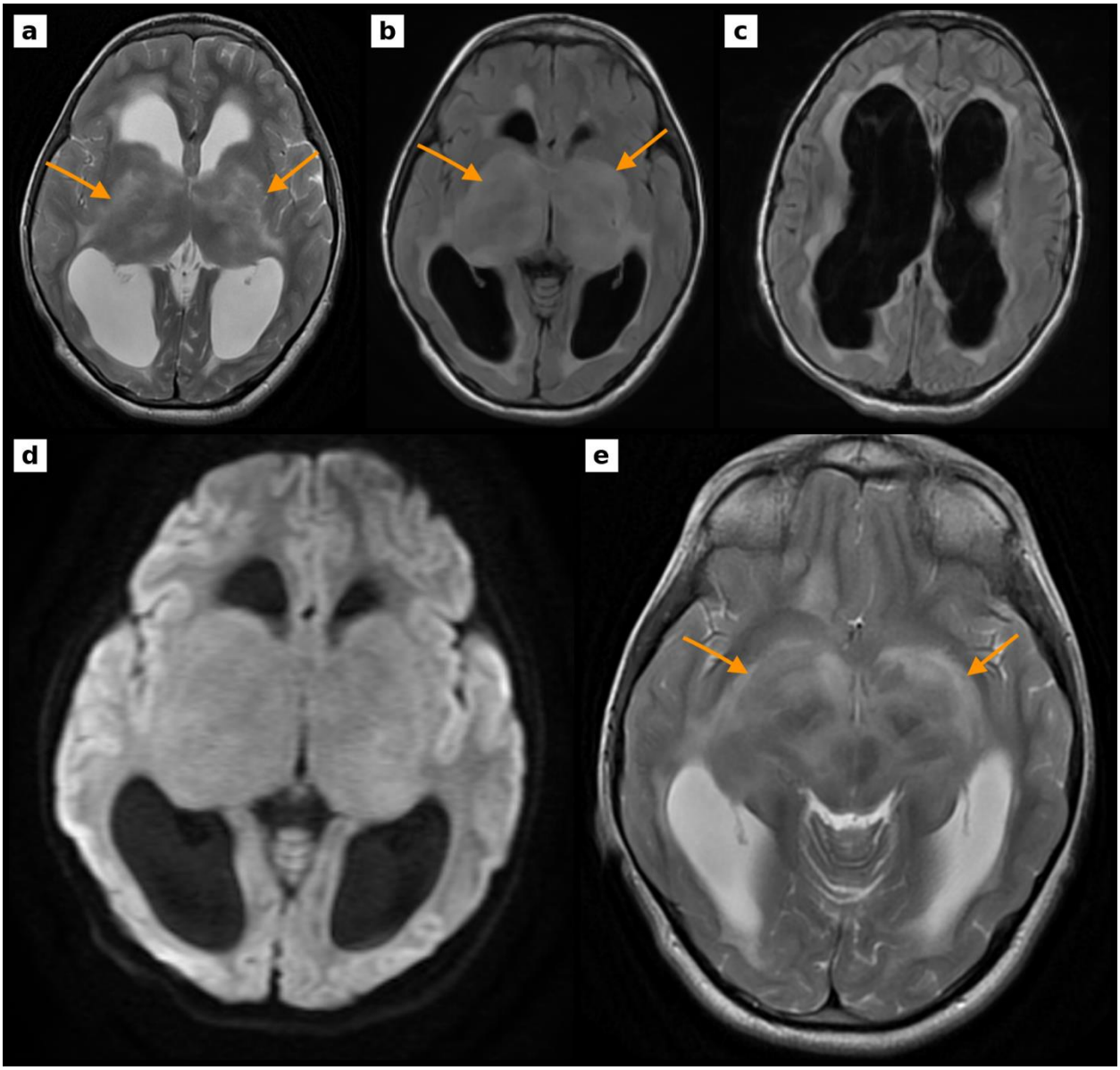

Figure 2. Axial MRI of the brain demonstrates posterior extension of the tumour and its secondary effects. (a) Axial T2-weighted image at the level of the lateral ventricles shows bulky, hyperintense enlargement of both thalami (yellow arrows) with dilated frontal horns. (b) Axial FLAIR image at the level of the third ventricle shows near-complete effacement of the third ventricle by the enlarged thalami and hypothalamus (yellow arrows). (c) Axial FLAIR image shows periventricular hyperintensity (periventricular ooze) accompanying the ventriculomegaly. (d) Axial diffusion-weighted image shows no corresponding diffusion restriction within the thalamic/hypothalamic abnormality. (e) Axial T2-weighted image at the level of the temporal horns and brainstem shows dilated temporal horns and bulky, mildly hyperintense bilateral thalamus, midbrain and pons (yellow arrows).

No abnormal parenchymal or leptomeningeal post-contrast enhancement was identified. The cerebellar hemispheres were unremarkable. An empty sella was noted incidentally. The visualised paranasal sinuses and mastoid air cells were clear.

These findings corresponded to modified Dodge/Taylor classification stage 4, with posterior optic pathway involvement including the optic chiasm and optic tracts, and deep extension into the thalamic and brainstem structures *[5]* (Table 2).

Table 2. Modified Dodge/Taylor (PLAN) classification applied to the present case

PLAN category	Anatomical site	Involvement in this case
1a	Single optic nerve	No (bilateral involvement present)
1b	Bilateral optic nerve	Yes
1c	Cisternal segment, optic nerve	Yes, bilateral
2a/2b	Chiasmatic (central/asymmetric)	Yes (laterality/symmetry of chiasmatic involvement not further specified)
3	Optic tracts	Yes, bilateral
4	Diffuse posterior pathway (radiations/deep extension)	Yes – thalamic, midbrain, and pontine extension
H+	Hypothalamic involvement	Yes
LM	Leptomeningeal dissemination	No
NF1	Neurofibromatosis type 1 status	Pending clinical/genetic correlation

PLAN, acronym denoting the four centres — Padua, Leeds, Augsburg, and Nottingham — whose patient cohorts underpinned this classification system's development and validation by Taylor et al.; also referred to as the modified Dodge classification; H, hypothalamus; LM, leptomeninges; NF1, neurofibromatosis type 1.

Impression

Extensive bilateral optic pathway glioma involving both optic nerves, the optic chiasm, and both optic tracts, with contiguous involvement of the hypothalamic/chiasmatic region, both thalami, midbrain, and pons; compression of the third ventricle causing upstream obstructive

hydrocephalus with periventricular ooze; modified Dodge/Taylor stage 4. Correlation for associated NF1 was recommended.

3.3 Patient Perspective

Given the patient's age and his altered sensorium at presentation, a first-person account of his experience of illness and care could not be obtained for this report.

4. Differential Diagnosis

The imaging differential diagnosis for bilateral, fusiform, non-enhancing enlargement of the optic nerves, chiasm, and posterior visual pathway is relatively narrow, and the pattern seen in this case argues strongly for a glial neoplasm over its principal mimics.

Optic neuritis typically causes more segmental and asymmetric nerve enlargement with acute-onset visual loss, frequent diffusion restriction in the acute phase, and, unlike the present case, post-contrast enhancement; visual symptoms in demyelinating disease are also generally more acute and more severe relative to the degree of imaging abnormality *[9]*.

Neurosarcoidosis and lymphomatous or leukaemic infiltration of the optic pathway usually enhance avidly and are frequently accompanied by leptomeningeal disease or other systemic manifestations, neither of which was present in this patient *[10,11]*.

Langerhans cell histiocytosis and idiopathic orbital inflammatory disease more typically produce asymmetric, painful, or extraconal soft-tissue masses rather than the smooth, symmetric, intrinsic nerve-and-chiasm enlargement seen here *[11]*.

Infectious and autoimmune or para-infectious encephalitis was clinically the leading alternative diagnosis in this child, given the febrile prodrome, neuroregression, and chorea. However, these processes classically produce cortical or deep grey/basal ganglia signal change and would not be expected to produce the tubular, fusiform enlargement of the optic nerves and chiasm that anchored the diagnosis in this case *[9,12]*.

Given the unusually extensive thalamic, hypothalamic, midbrain, and pontine abnormality in this case, and the absence of histopathological or molecular confirmation, a diffuse midline glioma, H3 K27-altered — a distinct, typically higher-grade World Health Organization-defined entity that characteristically arises in the thalamus, brainstem, and other midline structures of children — merits explicit consideration as an alternative to contiguous extension of an optic pathway glioma *[3,13]*. Several imaging features in this case argue against a primary or co-existing diffuse midline glioma: the abnormality was contiguous with, and centred on, the optic nerves and chiasm rather than originating independently within the thalamus or brainstem; it was symmetric and bilateral rather than the more commonly unilateral or asymmetric distribution reported for high-grade thalamic gliomas; and it lacked the diffusion restriction, necrosis, and the more infiltrative, ill-defined margins that frequently characterise high-grade midline gliomas on MRI, instead showing a well-defined, non-enhancing, non-restricting pattern throughout *[13]*. On balance, we interpret the thalamic, hypothalamic, midbrain, and pontine abnormality as contiguous posterior extension of a single bilateral optic pathway glioma rather than a separate or co-existing high-grade process, while acknowledging that this interpretation remains a radiological one made in the absence of tissue or molecular confirmation, and that a change in clinical trajectory or interval imaging appearance would warrant reconsideration of this differential, including biopsy.

The smooth, symmetric, fusiform contour of the abnormality; its contiguity with the chiasm and posterior visual pathway; and the absence of enhancement or diffusion restriction are, taken together, most consistent with optic pathway glioma and argue against each of the alternatives above.

5. Discussion

Optic pathway glioma is a low-grade (WHO grade 1) astrocytic tumour arising anywhere along the visual pathway from the optic nerve to the optic radiations, most frequently diagnosed in the first decade of life *[1,2,3]*. Approximately 15–20% of children with NF1 develop an OPG, while OPG itself is now recognised as a criterion for the clinical diagnosis of NF1 under the revised 2021 international consensus criteria, which also permit genetic confirmation by identification of a pathogenic *NF1* variant *[4]*. Bilateral optic nerve involvement, as in the present case, is characteristic of NF1-associated disease, whereas isolated chiasmatic or markedly posterior tumours without nerve involvement are more typical of sporadic OPG *[1]*. In this child, examination identified multiple café-au-lait macules and axillary freckling, which — together with the OPG itself — correspond to diagnostic criteria for NF1 under the revised 2021 international consensus criteria (six or more café-au-lait macules; axillary or inguinal freckling; optic pathway glioma); because the clinical diagnosis requires two or more criteria in an individual without an affected parent, this child meets, or closely approaches, the clinical diagnostic threshold, pending confirmatory evaluation, as no Lisch nodules, neurofibromas, or other stigmata were identified on examination and genetic testing had not yet been performed at the time of reporting. Clinical stigmata of NF1 can be absent or still emerging in children who do not yet meet diagnostic criteria, so dedicated clinical genetics evaluation using the revised 2021 criteria is warranted in any child

with OPG regardless of skin findings; in this child, the skin findings further support that evaluation *[4]*.

5.1 Chorea and Thalamic Involvement: Neuroanatomical Considerations

The chorea in this child is among the most clinically unusual features of this case. Chorea is classically a disorder of the basal ganglia–thalamocortical motor circuit, most often implicating the striatum (caudate and putamen) and subthalamic nucleus. The thalamus itself, however — through nuclei such as the ventral anterior and ventral lateral nuclei, which relay basal ganglia output to the motor and premotor cortex — is also an integral node of this same circuit, and focal thalamic lesions, including thalamic infarction, are a recognised, if less common, cause of hemichorea or chorea in both adults and children *[14]*. In this patient, bulky, infiltrative, bilateral tumour involvement of both thalami is therefore anatomically well positioned to disrupt thalamocortical relay and could plausibly contribute to the chorea observed. This proposed link, however, is an anatomical inference derived from the known motor-circuit pathways and the distribution of tumour on imaging, not a proven causal mechanism. No functional, electrophysiological, or neuropathological testing was performed or available to confirm that the thalamic tumour was the direct substrate of the chorea in this specific child. A contribution from the concurrent febrile illness or the broader diencephalic/midbrain involvement also cannot be entirely excluded on the available data. To our knowledge, chorea has not previously been reported as a presenting feature of optic pathway glioma, and we are not aware of a published case of bilateral thalamic extension of OPG presenting in this way; we therefore offer this as a clinical observation that warrants awareness, rather than an established disease mechanism. Notably, despite the extensive hypothalamic involvement demonstrated on imaging, this child did not manifest diencephalic syndrome — the pattern of failure to thrive, hyperactivity, and

hypermetabolism classically described in infants and very young children with hypothalamic optic pathway glioma *[6,15]* — consistent with this child's later age at presentation and reinforcing the atypical nature of the presenting features in this case.

5.2 Staging, Imaging Features, and Management

Since 1958, the Dodge classification has staged OPG by anatomical extent: nerve-only (stage 1), chiasmatic with or without nerve involvement (stage 2), and hypothalamic/posterior extension (stage 3). Taylor et al. proposed a modified, MRI-based system that more granularly documents the number, laterality, and precise anatomical location of tumour involvement, including separate categorisation of hypothalamic and other posterior structures, and validated it in a multicentre cohort; NF1-positive tumours more often involved both optic nerves and multiple sites, whereas NF1-negative tumours more often involved the central chiasm and hypothalamus *[5]*. Under this modified system, the present tumour — with bilateral nerve, chiasmatic, tract, hypothalamic, thalamic, midbrain, and pontine involvement — corresponds to an advanced, modified Dodge/Taylor stage 4 pattern, among the more extensive anatomical distributions described.

The clinical presentation of OPG is classically visual: proptosis, nystagmus, strabismus, or progressive visual loss in an older child, or diencephalic syndrome (failure to thrive with paradoxical alertness) in an infant with hypothalamic involvement *[1,6]*. Presentation with a movement disorder such as chorea, as seen in this patient, is not a recognised classical feature of OPG; its possible neuroanatomical basis is discussed in Section 5.1.

On MRI, OPG typically appears as fusiform, tortuous enlargement of the affected optic-pathway structures, iso- to hypointense to grey matter on T1W images and hyperintense on T2W/FLAIR images, usually without significant diffusion restriction. NF1-associated tumours can show a

characteristic “pseudo-cerebrospinal fluid” or double-intensity sign, in which a hyperintense (T2) or hypointense (T1) rim around the nerve corresponds to perineural arachnoidal gliomatosis rather than true enhancing tumour *[7]*. Gadolinium enhancement is variable and does not correlate with histological grade; the absence of enhancement in the present case, as in many OPGs, therefore does not argue against the diagnosis *[1,7]*.

Current consensus holds that radiological diagnosis is sufficient for typical hypothalamic-chiasmatic OPG in young children and for NF1-associated disease, without the need for tissue confirmation, reserving biopsy for atypical imaging or an equivocal clinical context *[1]*. Management is risk-adapted: asymptomatic or radiologically stable tumours are followed with serial ophthalmological assessment and interval MRI, while treatment is initiated for tumours that threaten vision, produce significant mass effect, or cause hydrocephalus or endocrinopathy, rather than on the basis of imaging findings alone *[16]*. Standardised imaging-based response assessment in trials now follows the Response Assessment in Pediatric Neuro-Oncology (RAPNO) recommendations, which emphasise T2/FLAIR-based measurement given the frequently non-enhancing, partly cystic nature of these tumours *[17]*. First-line systemic therapy remains carboplatin-based chemotherapy, while the MEK inhibitor selumetinib has become an established option for recurrent, refractory, or NF1-associated progressive disease on the strength of phase 2 trial data demonstrating durable radiographic and visual responses *[18]*. Most recently, the type II pan-RAF inhibitor tovorafenib received regulatory approval for relapsed or refractory BRAF-altered paediatric low-grade glioma, after the phase 2 FIREFLY-1 trial demonstrated an overall response rate of 67% by independent review. This broadens the targeted-therapy options now available for advanced, recurrent, or treatment-resistant OPG in general *[19]*. No treatment or outcome data are available for this patient; the therapies discussed above are the evidence-based

options that would be considered under multidisciplinary evaluation, not treatments reported in this case. Surgery has a limited, largely palliative or diagnostic role — principally cerebrospinal fluid diversion for obstructive hydrocephalus or subtotal debulking for mass effect — since gross total resection is rarely feasible or desirable given the tumour's location within the visual pathway and hypothalamus *[16]*.

Prognosis in OPG is influenced principally by tumour extent, the degree of hypothalamic and posterior-pathway involvement, visual function at presentation, and NF1 status, with NF1-associated tumours generally following a more indolent course than sporadic disease *[1,16]*. Applying these factors to the present case, the extensive bilateral and posterior distribution of the tumour and the presence of obstructive hydrocephalus are unfavourable features, whereas any protective effect of an eventual NF1 diagnosis remains to be determined; long-term prognosis could not be assessed in this report, as outcome data were not available at the time of writing.

In the present case, the near-complete effacement of the third ventricle with an Evans index of 0.54 indicates clinically significant obstructive hydrocephalus that constitutes a neurosurgical priority independent of, and typically preceding, oncological treatment planning. Multidisciplinary input from paediatric neurosurgery, neuro-oncology, ophthalmology, and endocrinology is indicated given the hypothalamic involvement, and formal neuropsychiatric and movement-disorder assessment may help clarify the contribution of the tumour to the chorea and guide symptomatic management. The type of intervention indicated — cerebrospinal fluid diversion for the hydrocephalus and consideration of MEK- or RAF-directed systemic therapy or conventional chemotherapy for the tumour, guided by multidisciplinary evaluation — follows the evidence-based practice outlined above; treatment administration and clinical outcome fall outside the diagnostic-imaging scope of this report and were not available for inclusion.

5.3 Strengths and Limitations

This report has several limitations. First, it is cross-sectional and diagnostic in focus: it describes the index presentation only, and no long-term follow-up was available, so treatment administration and longer-term visual, endocrine, and neurological outcomes — including resolution of the chorea and neuroregression — could not be assessed. This is a clinically important gap: in an Italian multicentre series of nine children with optic pathway glioma presenting with diencephalic syndrome (median age 14 months), neuroendocrine disorders were diagnosed in seven (77.8%) and neurological or cognitive sequelae in five at last follow-up; that cohort was younger and clinically different from this child, but the findings underline the value of structured longitudinal surveillance in hypothalamic OPG *[15]*. Second, NF1 genetic testing, planned as part of the subsequent evaluation, had not been performed at the time of writing, so genetic confirmation of NF1 is pending. Third, no histopathological or molecular confirmation was available, so the diagnosis is radiological. Fourth, as a single-patient report, the findings cannot establish how representative this presentation is of OPG with posterior extension more broadly, and the proposed link between thalamic involvement and chorea remains an anatomical inference rather than a confirmed causal mechanism. The principal strength of this report is the detailed, multisequence MRI characterisation of an anatomically extensive tumour distribution that is infrequently illustrated in the literature, together with a systematic staging and differential-diagnosis framework intended to aid recognition of similar cases.

6. Conclusion

Extensive bilateral optic pathway glioma with hypothalamic, thalamic, and brainstem extension — modified Dodge/Taylor stage 4 disease — is an uncommon anatomical pattern that can present

with predominantly non-visual neurological features, including neuroregression and chorea, rather than the classical visual symptoms of OPG, and can be complicated by obstructive hydrocephalus requiring urgent recognition. A high index of suspicion, combined with recognition of the characteristic bilateral, fusiform, non-enhancing MRI appearance of the optic pathway, allows OPG to be reliably distinguished from infectious, inflammatory, and infiltrative mimics, and directs timely multidisciplinary management and evaluation for underlying NF1.

Learning Points

- Bilateral, fusiform, non-enhancing, non-diffusion-restricting enlargement of the optic nerves–chiasm–tracts is the MRI hallmark of optic pathway glioma and should be specifically sought in children with unexplained thalamic, hypothalamic, or brainstem T2/FLAIR signal change.
- Posterior extension into the hypothalamus, thalami, and brainstem (modified Dodge/Taylor stage 4) is uncommon and can be associated with non-visual presentations, including neuroregression and, in this child, chorea (a link inferred from anatomy, not proven), which may mimic infectious or autoimmune encephalitis.
- Obstructive hydrocephalus from third-ventricular compression is a neurosurgical priority that requires prompt recognition and, typically, cerebrospinal fluid diversion independent of oncological treatment planning.
- Every child with OPG, and especially bilateral disease, warrants dedicated clinical and, where indicated, genetic evaluation for NF1 using the revised 2021 diagnostic criteria, even in the absence of classical skin stigmata.

- Radiological diagnosis is considered sufficient for typical hypothalamic-chiasmatic OPG in young children and for NF1-associated disease; biopsy is reserved for atypical imaging or clinical features.
- MEK inhibitors (e.g., selumetinib) and, most recently, the RAF inhibitor tovorafenib have expanded the systemic treatment options for progressive or refractory OPG beyond conventional chemotherapy.

List of Abbreviations

BRAF, B-Raf proto-oncogene, serine/threonine kinase; CSF, cerebrospinal fluid; DWI, diffusion-weighted imaging; FIESTA, fast imaging employing steady-state acquisition; FLAIR, fluid-attenuated inversion recovery; MEK, mitogen-activated protein kinase kinase; MRI, magnetic resonance imaging; NF1, neurofibromatosis type 1; OPG, optic pathway glioma; RAF, rapidly accelerated fibrosarcoma (kinase family); RAPNO, Response Assessment in Pediatric Neuro-Oncology; STIR, short-tau inversion recovery; SWI, susceptibility-weighted imaging; T1W, T1-weighted; T2W, T2-weighted; WHO, World Health Organization.

Author contributions

Contributions are reported using the CRediT (Contributor Roles Taxonomy). Author initials: N.M. = Naman Maheshwari; A.G. = Archit Gupta; K.S. = Kartik Singh; N.G. = Naman Gupta; P.S. = Pankaj Sharma. Conceptualization, investigation, visualization, writing – original draft preparation, writing – review and editing: N.M.; Investigation, visualization, writing – original draft preparation, writing – review and editing: A.G.; Formal analysis, writing – review and editing: K.S.; Visualization, writing – original draft preparation, writing – review and editing:

N.G.; Conceptualization, formal analysis, writing – original draft preparation, writing – review and editing, supervision: P.S. All authors read and approved the final manuscript.

Standards of Reporting

This case report has been prepared and reported in accordance with the CARE (Case Report) guidelines for the reporting of clinical case reports. The completed CARE checklist, cross-referencing each checklist item to its location in this manuscript, is submitted as a supplementary file accompanying this manuscript.

Ethics Committee Approval and Consent to Participate

This case report was exempted from formal ethics committee approval by the Institutional Ethics Committee of AIIMS Rishikesh, in accordance with institutional policy for single anonymised case reports, as it describes findings from clinically indicated investigations performed as part of routine patient care without any research-related intervention. Written informed consent to participate was obtained from the patient's legally authorised representative given the patient's altered sensorium at presentation, and from the patient directly once mental status normalised. This consent was a discrete, procedural authorisation for the publication of anonymised clinical and imaging details; it does not reflect a structured patient-interview or follow-up assessment. No first-person narrative of the patient's illness experience was separately elicited or recorded, and no clinical follow-up, treatment, or outcome data beyond the index admission were available to the authors at the time of writing.

Human Rights Statement

All procedures concerning this patient were in accordance with the ethical standards of the responsible institutional committee and with the 1964 Declaration of Helsinki and its later amendments, including the 2013 revision.

Consent for Publication

Written informed consent for publication of anonymised clinical details and imaging was obtained from the patient's legally authorised representative and, once his mental status normalised, from the patient.

Availability of Data and Materials

The imaging data that support the findings of this case report are available from the corresponding author on reasonable request, subject to institutional data-sharing policies and patient confidentiality.

Conflicts of Interest

The authors declare that they have no competing interests.

Funding

The authors declare that no funding, grants, or other financial support were received for this study.

Acknowledgments

None

AI-declaration

ChatGPT (OpenAI) was used solely as a writing-assistance tool to assist with grammar correction, language refinement, and improving the clarity and readability of the authors' original text, under direct author supervision; all scientific content, clinical data, literature interpretation, and imaging interpretation were generated, reviewed, and verified by the human authors, who take full accountability for them. A detailed description of how the tool was used is provided in the Materials and Methods section of the manuscript.

References

[1] Cassina, M.; Frizziero, L.; Opocher, E.; Parrozzani, R.; Sorrentino, U.; Viscardi, E.; Miglionico, G.; Midena, E.; Clementi, M.; Trevisson, E. Optic pathway glioma in type 1 neurofibromatosis: review of its pathogenesis, diagnostic assessment, and treatment recommendations. Cancers (Basel) 2019, 11 (11), 1790.

[2] Huang, M.; Patel, J.; Gasalberti, D. P.; Patel, B. C. Optic Nerve Glioma. In StatPearls [Internet]; StatPearls Publishing: Treasure Island, FL, 2025 (updated Mar 26, 2024).

[3] Louis, D. N.; Perry, A.; Wesseling, P.; Brat, D. J.; Cree, I. A.; Figarella-Branger, D.; Hawkins, C.; Ng, H. K.; Pfister, S. M.; Reifenberger, G.; Soffietti, R.; von Deimling, A.; Ellison, D. W. The 2021 WHO Classification of Tumors of the Central Nervous System: a summary. Neuro Oncol. 2021, 23 (8), 1231–1251.

[4] Legius, E.; Messiaen, L.; Wolkenstein, P.; Pancza, P.; Avery, R. A.; Berman, Y.; Blakeley, J.; Babovic-Vuksanovic, D.; Cunha, K. S.; Ferner, R.; Fisher, M. J.; Friedman, J. M.; Gutmann, D. H.; Kehrer-Sawatzki, H.; Korf, B. R.; Mautner, V.-F.; Peltonen, S.; Rauen, K. A.; Riccardi,

V.; Schorry, E.; Stemmer-Rachamimov, A.; Stevenson, D. A.; Tadini, G.; Ullrich, N. J.; Viskochil, D.; Wimmer, K.; Yohay, K.; International Consensus Group on Neurofibromatosis Diagnostic Criteria (I-NF-DC). Revised diagnostic criteria for neurofibromatosis type 1 and Legius syndrome: an international consensus recommendation. Genet. Med. 2021, 23 (8), 1506–1513.

[5] Taylor, T.; Jaspan, T.; Milano, G.; Gregson, R.; Parker, T.; Ritzmann, T.; Benson, C.; Walker, D.; PLAN Study Group. Radiological classification of optic pathway gliomas: experience of a modified functional classification system. Br. J. Radiol. 2008, 81 (970), 761–766.

[6] Walker, D. A.; Aquilina, K.; Spoudeas, H.; Pilotto, C.; Gan, H.-W.; Meijer, L. A new era for optic pathway glioma: a developmental brain tumor with life-long health consequences. Front. Pediatr. 2023, 11, 1038937.

[7] Patel, H.; Chakrabarty, B.; Dubey, R.; Kumar, A.; Gulati, S. Optic nerve glioma in neurofibromatosis: radiological clues to diagnosis in a young child. J. Pediatr. Neurosci. 2021, 16 (3), 264–265.

[8] Charan, B. D.; Mishra, N.; Bathla, R.; Agarwal, S. Optic pathway glioma of infancy: a case report and literature review. SN Compr. Clin. Med. 2025, 7, 452.

[9] George, E.; Russ, J. B.; Validrighi, A.; Early, H.; Mamlouk, M. D.; Glenn, O. A.; Francisco, C. M.; Waubant, E.; Lindan, C.; Li, Y. Clinical and imaging findings in children with myelin oligodendrocyte glycoprotein antibody-associated disease (MOGAD): from presentation to relapse. AJNR Am. J. Neuroradiol. 2024, 45 (2), 229–235.

[10] Ng, K. L.; McDermott, N.; Romanowski, C. A.; Jackson, A. Neurosarcoidosis masquerading as glioma of the optic chiasm in a child. Postgrad. Med. J. 1995, 71 (835), 265–268.

[11] Rao, A. A.; Naheedy, J. H.; Chen, J. Y.-Y.; Robbins, S. L.; Ramkumar, H. L. A clinical update and radiologic review of pediatric orbital and ocular tumors. J. Oncol. 2013, 2013, 975908.

[12] Mohammad, S. S.; Angiti, R. R.; Biggin, A.; Morales-Briceño, H.; Goetti, R.; Perez-Dueñas, B.; Gregory, A.; Hogarth, P.; Ng, J.; Papandreou, A.; et al. Magnetic resonance imaging pattern recognition in childhood bilateral basal ganglia disorders. Brain Commun. 2020, 2 (2), fcaa178.

[13] Rodriguez, D.; Calmon, R.; Sanchez Aliaga, E.; et al. MRI and molecular characterization of pediatric high-grade midline thalamic gliomas: the HERBY phase II trial. Radiology 2022, 304 (1), 174–182.

[14] Li, Z. S.; Fang, J. J.; Xiang, X. H.; Zhao, G. H. Hemichorea due to ipsilateral thalamic infarction: a case report. World J. Clin. Cases 2021, 9 (19), 5287–5293.

[15] De Martino, L.; Picariello, S.; Triarico, S.; Improda, N.; Spennato, P.; Capozza, M. A.; Grandone, A.; Santoro, C.; Cioffi, D.; Attinà, G.; et al. Diencephalic Syndrome Due to Optic Pathway Gliomas in Pediatric Patients: An Italian Multicenter Study. Diagnostics 2022, 12 (3), 664.

[16] Walker, D. A.; Liu, J.; Kieran, M.; Jabado, N.; Picton, S.; Packer, R.; St Rose, C.; CPN Paris 2011 Conference Consensus Group. A multi-disciplinary consensus statement concerning surgical approaches to low-grade, high-grade astrocytomas and diffuse intrinsic pontine gliomas in childhood (CPN Paris 2011) using the Delphi method. Neuro Oncol. 2013, 15 (4), 462–468.

[17] Fangusaro, J.; Witt, O.; Hernáiz Driever, P.; Bag, A. K.; de Blank, P.; Kadom, N.; et al. Response assessment in paediatric low-grade glioma: recommendations from the Response

Assessment in Pediatric Neuro-Oncology (RAPNO) working group. Lancet Oncol. 2020, 21 (6), e305–e316.

[18] Fangusaro, J.; Onar-Thomas, A.; Poussaint, T. Y.; Wu, S.; Ligon, A. H.; Lindeman, N.; Banerjee, A.; Packer, R. J.; Kilburn, L. B.; Goldman, S.; et al. Selumetinib in paediatric patients with BRAF-aberrant or neurofibromatosis type 1-associated recurrent, refractory, or progressive low-grade glioma: a multicentre, phase 2 trial. Lancet Oncol. 2019, 20 (7), 1011–1022.

[19] Kilburn, L. B.; Khuong-Quang, D.-A.; Hansford, J. R.; Landi, D.; van der Lugt, J.; Leary, S. E. S.; Driever, P. H.; Bailey, S.; Perreault, S.; McCowage, G.; et al. The type II RAF inhibitor tovorafenib in relapsed/refractory pediatric low-grade glioma: the phase 2 FIREFLY-1 trial. Nat. Med. 2024, 30 (1), 207–217.