Cancer Research and Therapy Connect
ISSN: 3105-3629
2026, Article ID. 2026.0017, Cite as: https://doi.org/10.69709/CRCT.2026.334455

SCIFINITI PUBLISHING

Review Article

OPEN ACCESS

Pediatric Pure Erythroid Leukemia: Diagnostic Challenges, Immunophenotypic Features, Molecular Pathogenesis, and Practical Diagnostic Approach

Yehezkiel Yonathan[✉,*], **Ratu Purwanti**[✉]

Department of Clinical Pathology, Faculty of Medicine, Universitas Padjadjaran, Bandung 40161, Indonesia

Article History
Received: June 25, 2026 Accepted: August 25, 2026 Published: October 05, 2026

Abstract

Pure erythroid leukemia (PEL), classified as acute erythroid leukemia in the 2022 World Health Organization classification, is a rare and aggressive acute myeloid neoplasm characterized by the predominance of immature erythroid precursors in the bone marrow and marked impairment of erythroid maturation. Recognition in children remains difficult because adult PEL is usually defined by biallelic TP53 alteration and complex karyotype, whereas reported childhood disease includes NUP98-, NFIA-, CIC-, and other fusion-defined presentations. This structured narrative review provides a comprehensive overview of the classification, morphology, immunophenotype, molecular pathogenesis, genotype-phenotype heterogeneity, differential diagnosis, treatment, prognosis, measurable residual disease (MRD), and a practical diagnostic workflow. Evidence was weighted according to the type and quality of the source, with priority given to the World Health Organization (WHO) and International Consensus Classification (ICC) documents, multicenter pediatric cohorts, comparative molecular studies, and molecularly characterized case series. No standardized treatment approach specific to pediatric PEL has been established to date. Most reported pediatric patients receive protocol-based acute myeloid leukemia therapy, while hematopoietic stem cell transplantation is considered based on adverse genetic features, treatment response, measurable residual disease (MRD) status, relapse status, and extramedullary involvement. The largest pediatric cooperative-group dataset reported 5-year overall and event-free survival of approximately 20% for the PEL subset, although genotype-specific outcome estimates remain limited. MRD assessment should integrate baseline immunophenotypic characterization with molecular monitoring when a stable fusion or mutation is available, while cerebrospinal fluid monitoring should be considered in patients with documented central nervous system involvement. Integrated diagnosis and management require coordinated morphology, flow cytometry, immunohistochemistry, cytogenetics, DNA sequencing, and early RNA-based fusion testing, with explicit recognition of the limited evidence base.

Keywords:
pediatric acute myeloid leukemia; pure erythroid leukemia; molecular pathogenesis; immunophenotyping; erythroblastic sarcoma

1. Introduction

Pure erythroid leukemia (PEL) is an exceptionally uncommon acute leukemia and remains a difficult diagnosis in pediatric hematopathology. In conventional acute myeloid leukemia (AML), the abnormal population is usually recognizable as myeloblasts; in PEL, the malignant compartment consists predominantly of immature erythroid precursors with abrupt maturation arrest. This lineage pattern creates several diagnostic pitfalls. Peripheral blood may contain few obvious blasts, aspirates may be

* **Corresponding Author:**
Yehezkiel Yonathan, Department of Clinical Pathology, Faculty of Medicine, Universitas Padjadjaran, Bandung 40161, Indonesia, yehezkielyonathan@gmail.com

© 2026 Copyright by the Authors.
Licensed as an open access article using a CC BY 4.0 license.

dilute or necrotic, and blastoid erythroid cells can resemble lymphoblasts, minimally differentiated AML, megakaryoblasts, plasma cell neoplasms, or non-hematopoietic small round-cell tumors. Morphology therefore serves as an initial diagnostic entry point rather than the definitive basis for diagnosis. Current classification systems provide the necessary diagnostic framework [1,2], while earlier WHO classifications and hematopathology reviews remain valuable for understanding the evolution of diagnostic thresholds and lineage assignment [3–5]. A defensible diagnosis requires concordant marrow architecture, cytology, flow cytometry, immunohistochemistry, cytogenetics, and molecular testing [6–8]. In children, ribonucleic acid (RNA)-based fusion testing deserves early consideration when the morphology and phenotype suggest erythroid-lineage leukemia [9].

The classification of erythroid-predominant leukemias has narrowed considerably over time. The older French-American-British AML-M6 category combined biologically different disorders, including cases that would now be classified as myelodysplastic neoplasms, AML with myelodysplasia-related genetics, therapy-related AML, or other genomically defined AML subtypes. In contemporary practice, true PEL is not merely characterized by erythroid hyperplasia with dysplasia; rather, it represents a leukemic proliferation dominated by immature erythroid precursors. The 2022 World Health Organization (WHO) classification retains acute erythroid leukemia as a distinct morphological entity, whereas the 2022 International Consensus Classification (ICC) classifies many TP53-mutated adult cases under acute myeloid leukemia (AML) with mutated TP53 [1,2]. This difference matters clinically because terminology affects risk communication, trial eligibility, and how older AML-M6 studies are interpreted.

The pediatric literature requires separate interpretation. Adult PEL is strongly linked to advanced age, antecedent or therapy-related myeloid disease, complex or monosomal karyotype, chromosome 5 and 7 abnormalities, and poor survival [10–12]. Biallelic TP53 inactivation and adverse cytogenetics are central to this adult model [13,14]. Pediatric reports, however, point to broader heterogeneity, including NUP98 rearrangements [9], NFIA::CBFA2T3 and NFIA::RUNX1T1 fusions [15,16], other erythroid leukemia-associated rearrangements [17–19], CNS or soft-tissue erythroblastic sarcoma presentations [20,21], marrow-based adolescent acute erythroid leukemia [22], NFIA::CBFA2T3-associated erythroblastic sarcoma or PEL [23], CIC-rearranged disease [24], multi-institutional erythroblastic sarcoma series [25], and more recent NFIA::CBFA2T3 reports with disseminated or cerebrospinal-fluid-based disease [26,27]. Experimental work on NFIA-ETO2 supports a direct maturation-arrest mechanism, particularly in cooperation with mutant TP53 [28]. Limited existing evidence suggests that some children present with central nervous system or soft-tissue disease before marrow disease is obvious. These observations argue against considering pediatric PEL merely an age-shifted counterpart of adult TP53-mutated AML. They also highlight substantial gaps in the evidence regarding treatment, prognosis, MRD standardization, and genotype-specific risk stratification. This review therefore integrates diagnostic reasoning with treatment principles, prognostic stratification, MRD monitoring, and practical reporting considerations.

2. Methods

This narrative review used a structured search and evidence-weighting process informed by the SANRA framework for narrative reviews [29]. PubMed, including MEDLINE-indexed records, was searched from 1 January 2000 to 13 June 2026, with earlier landmark publications retained when necessary to provide historical context for disease classification and erythroid biology. The review was restricted to English-language full-text publications. Four Boolean search blocks were used: (1) (“pure erythroid leukemia” OR “acute erythroid leukemia” OR erythroleukemia OR “erythroblastic sarcoma”) AND (classification OR morphology OR immunophenotype OR diagnosis OR WHO OR ICC); (2) the same disease block AND (child* OR pediatric* OR infant* OR adolescent*) AND (NUP98 OR NFIA OR CBFA2T3 OR RUNX1T1 OR TP53 OR EPOR OR JAK2 OR CIC OR GATA1); (3) the same disease block AND (treatment OR chemotherapy OR transplantation OR HSCT OR outcome OR survival OR prognosis OR relapse); and (4) the same disease block AND (“measurable residual disease” OR “minimal residual disease” OR MRD OR flow cytometry OR “molecular monitoring” OR cerebrospinal fluid OR CSF). The term “minimal residual disease” was included only as a legacy search synonym; throughout the manuscript, MRD refers to measurable residual disease. Backward and forward citation screening of key articles, together with targeted searches of journal websites, was performed to identify additional classification documents, mechanistic studies, and recent molecularly characterized pediatric reports.

Y.Y. performed title and abstract screening, followed by full-text assessment. R.P. verified the final included set and reviewed uncertain eligibility decisions; the authors resolved disagreements through discussion. Because the initial database hit counts were not prospectively archived, the numerical flow was reconstructed

2026, Vol. 2, Article ID. 2026.0017
https://doi.org/10.69709/CRCT.2026.334455

during revision from the final deduplicated source library. The reconstructed library contained 61 unique English-language full-text publications. All 61 publications were reassessed against the final eligibility criteria and retained in the narrative synthesis; no additional publications were excluded during this reconstructed audit. Publications were eligible for inclusion if they addressed official classification, diagnostic criteria, erythroid morphology or immunophenotype, pediatric or fusion-defined PEL, erythroblastic sarcoma, molecular pathogenesis, Down syndrome-associated mimics, treatment, transplantation, prognosis, or MRD. For interpretation, evidence was grouped into the same five priority categories shown in Figure 1: Highest, WHO or ICC classification documents and consensus guidance; High, multicenter or cooperative-group cohorts; Moderate, comparative clinicopathologic or molecular studies; Limited, small series and molecularly characterized case reports, including representative single-case reports; and Exploratory, preclinical models, drug-sensitivity studies, or hypothesis-generating targeted-therapy data. Single-case reports are therefore included within the Limited category, whereas the Exploratory category is reserved for preclinical or hypothesis-generating evidence and is not combined with case-report evidence. Adult studies were included only when pediatric evidence was unavailable or when they clarified classification, TP53 biology, treatment resistance, MRD methodology, or investigational targets. Abstract-only reports, duplicate descriptions without additional information, non-English articles, studies limited to reactive erythroid hyperplasia, and reports without sufficient lineage or molecular detail were excluded during the original literature selection and were not represented in the reconstructed final library.

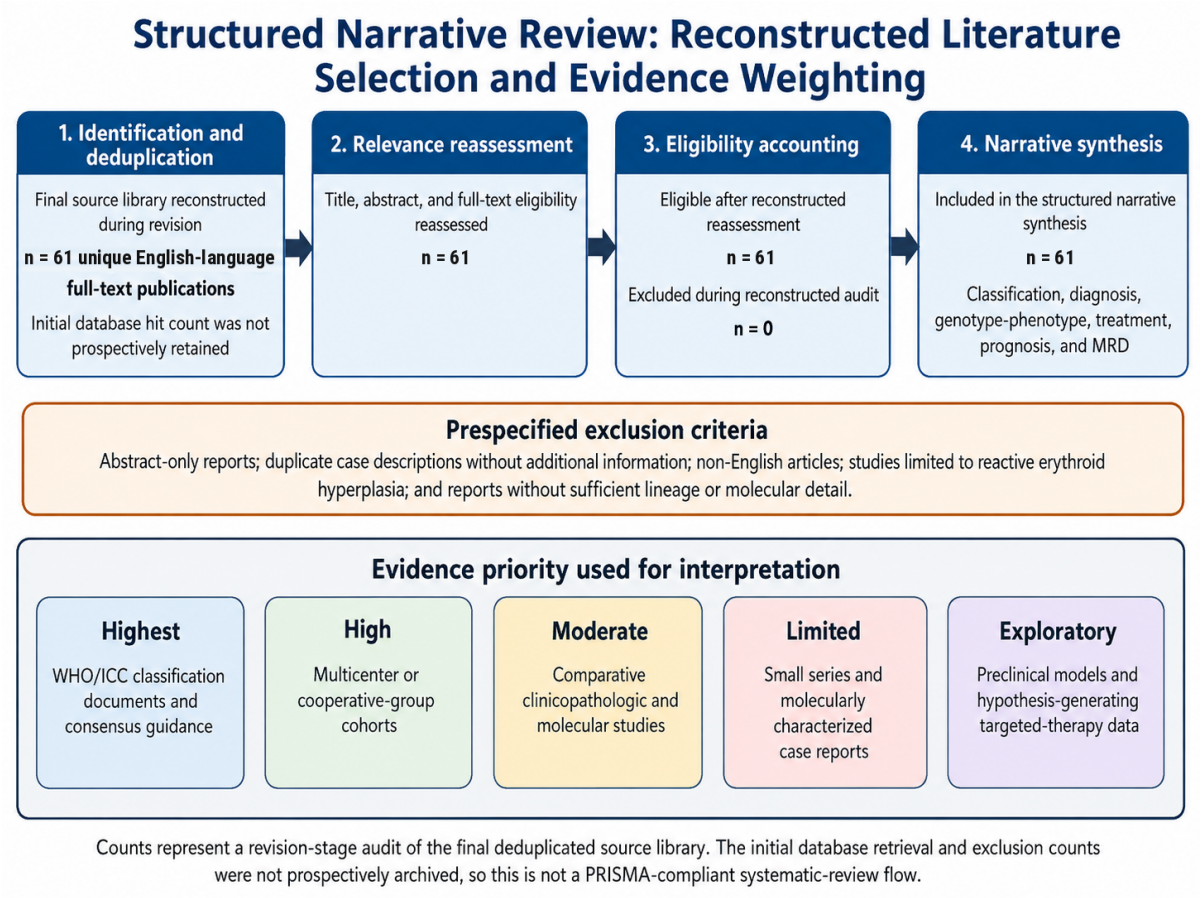

Figure 1: Reconstructed literature selection accounting and evidence weighting for this structured narrative review. Counts represent a revision-stage audit of the final deduplicated source library because initial database hit and exclusion counts were not prospectively archived. The evidence-priority categories correspond directly to the Methods section: Highest, High, Moderate, Limited, and Exploratory. Single-case reports are included within Limited, whereas preclinical and hypothesis-generating evidence is categorized separately as Exploratory.

Evidence statements were calibrated according to the strength of the supporting evidence. Diagnostic statements derived from the WHO or ICC are identified as classification-based conclusions. Findings from multicenter or cooperative-group cohorts are presented as the strongest available clinical evidence, whereas comparative clinicopathologic and molecular studies are considered moderate-level evidence. Small series and molecularly characterized case reports, including representative single cases, are treated as limited evidence and are not used as validated prognostic rules. Preclinical models, drug-sensitivity studies, and hypothesis-generating targeted-therapy data are labeled exploratory and do not constitute treatment recommendations. Because this is a narrative review rather than a systematic review or meta-analysis, no pooled effect estimates or formal risk-of-bias score was calculated. Figure 1 summarizes the reconstructed source-library accounting and this five-category evidence hierarchy. The figure is not presented as a PRISMA-compliant systematic-review flow.

3. Definition and Classification

PEL is best characterized as an acute leukemia dominated by immature erythroid precursors, typically exhibiting severe maturation arrest at the proerythroblast or pronormoblast stage. The 2022 WHO framework recognizes this entity as acute erythroid leukemia (previously termed pure erythroid leukemia) within acute myeloid leukemia defined by differentiation [1]. Historical WHO revisions and hematopathology reviews describe commonly used thresholds of at least 80% erythroid precursors and at least 30% proerythroblasts, although wording has varied across classifications and reports [3–5]. These thresholds provide a basis for classification; however, sampling-related limitations can compromise the accuracy of cell counting. Aspirate dilution, a dry tap, marrow fibrosis, necrosis, marked dyserythropoiesis, or extramedullary presentation may render the differential cell count unreliable. In such cases, biopsy architecture, erythroid immunohistochemistry, and genomic evidence of clonality carry greater diagnostic weight [6–8].

The central diagnostic challenge is not simply determining whether erythroid cells are increased in number, but establishing whether they are neoplastic and developmentally arrested. Erythroid hyperplasia may be reactive, nutritional, regenerative, drug-induced, or secondary to hemolysis. It can also accompany myelodysplastic neoplasms and AML with myelodysplasia-related features. PEL differs because the abnormal population is not a normally maturing erythroid series; it is a monomorphic or near-monomorphic population of immature erythroid blasts that displaces normal hematopoiesis. A useful diagnostic report should therefore document marrow cellularity, erythroid percentage, proerythroblast proportion, presence or absence of a separate myeloblast population, dysplasia in non-erythroid lineages, fibrosis, p53 staining pattern when performed, flow cytometry findings, and the results of karyotype, fluorescence in situ hybridization (FISH), next-generation sequencing (NGS), and fusion testing [6–8].

In pediatric patients, reporting is best framed by integrating morphological and genomic findings rather than forcing every case into an adult-derived classification category. WHO terminology preserves the erythroid phenotype, while ICC terminology highlights TP53-mutated AML biology when TP53 criteria are fulfilled. A child with a NUP98 or NFIA-related fusion, however, should not be described as though the adult TP53-mutated paradigm fully explains the disease. Practical diagnostic terminology may include acute erythroid leukemia/pure erythroid leukemia, with the specific genetic lesion identified when erythroid-lineage leukemia is supported; AML with mutated TP53 and a pure erythroid phenotype when the diagnostic criteria for TP53-mutated AML are met; or erythroblastic sarcoma, with the specific fusion and bone marrow involvement status reported when the initial presentation is a mass lesion. Such integrated wording communicates lineage, genetics, and risk without overstating certainty [6–8]. Table 1 summarizes key classification issues relevant to pediatric PEL.

Table 1: Classification issues relevant to pediatric pure erythroid leukemia.

Framework	Key Point	Practical Implication
WHO 2022	Recognizes acute erythroid leukemia as an erythroid-lineage AML dominated by immature erythroid precursors.	Useful for preserving the morphologic and lineage-based diagnosis.
ICC 2022	Classifies most TP53-mutated cases as AML with mutated TP53.	Highlights adverse biology and the need to document TP53 allelic status.
Pediatric practice	Requires morphology plus genomic testing, not adult extrapolation alone.	Report erythroid percentages, marker profile, karyotype, TP53 status, and fusion results.

2026, Vol. 2, Article ID. 2026.0017
https://doi.org/10.69709/CRCT.2026.334455

4. Pediatric Epidemiology and Clinical Presentation

PEL is rare across all age groups and is particularly uncommon in children. The true incidence in the pediatric population remains uncertain because earlier reports used to overlap diagnostic terminology, including AML-M6, erythroleukemia, pure erythroid leukemia, erythroblastic sarcoma, acute undifferentiated leukemia, and AML not otherwise specified. Reclassification under current WHO and ICC systems further limits comparison across cohorts. Adult AML studies indicate that PEL represents only a small fraction of cases [10]. Pediatric evidence is much thinner and comes mainly from cooperative group data [9], NFIA-associated case reports [15,16], recent erythroblastic sarcoma reports [20,21], and cytogenetic or mechanistic descriptions of rarer erythroid fusion events [17–19,28]. This limited evidence base has practical consequences: clinicians may not consider PEL early, and no pediatric PEL-specific therapeutic standard exists.

Clinical presentation usually reflects bone marrow failure rather than a distinctive leukemia syndrome. Children may present with pallor, fatigue, fever, recurrent infection, bruising, mucosal bleeding, petechiae, bone pain, or a generally poor clinical condition. Hepatomegaly and splenomegaly can occur but are non-specific. Laboratory findings typically include anemia and thrombocytopenia, with variable leukocyte counts. Circulating blasts may be absent, low, or morphologically ambiguous. Lactate dehydrogenase and uric acid may rise with high tumor burden. Because erythroid blasts may not be readily recognized as leukemic blasts on automated or manual peripheral blood examination, persistent or unexplained cytopenias accompanied by abnormal nucleated erythroid forms should prompt bone marrow evaluation. Extramedullary disease deserves particular attention in children. Erythroblastic sarcoma may involve the central nervous system, skull, spine, soft tissue, lymph nodes, or other sites and can be mistaken for lymphoma, myeloid sarcoma, Ewing sarcoma, rhabdomyosarcoma, poorly differentiated carcinoma, or inflammatory lesions. Immunohistochemistry is often decisive because the tumor may be CD45-negative or only weakly positive and may lack conventional myeloid markers. A panel including CD71, E-cadherin, CD36, glycophorin A, hemoglobin, GLUT1, CD117, CD34, myeloperoxidase, CD41, CD61, cytokeratin, desmin, and lymphoid markers helps prevent misclassification. CNS or infant erythroblastic sarcoma presentations have been associated with NFIA-related fusions [15,16], and recent pediatric reports continue to broaden this spectrum [20,21]. Sufficient tissue should be reserved for cytogenetic and RNA-based testing because rare or cryptic fusions may provide the decisive diagnostic clue [17–19,28].

Record age and constitutional context carefully. In neonates and infants, transient abnormal myelopoiesis (TAM) and myeloid leukemia of Down syndrome (ML-DS) must remain in the differential diagnosis, including in phenotypically subtle or mosaic trisomy 21. These disorders may exhibit megakaryocytic and erythroid features, as well as GATA1 mutations, and may be mistaken for erythroid leukemia when the lineage work-up is incomplete [30,31]. Their progression patterns and clinical spectrum differ from classic PEL [32–34]. Broader Down syndrome leukemia risk and the molecular evolution from TAM to ML-DS have been characterized separately [35,36], and additional genomic studies have clarified cooperating lesions during progression [37–39]. In suspected pediatric PEL, clinical history, physical examination, karyotype, assessment for constitutional or mosaic trisomy 21 when indicated, and GATA1 mutation testing are therefore not peripheral details; they are part of the diagnostic framework. Table 2 summarizes the pediatric reports most relevant to acute erythroid leukemia/pure erythroid leukemia and erythroblastic sarcoma. These cases should not be interpreted as constituting a mature epidemiologic dataset. Rather, they are better viewed as evidence that childhood erythroid-lineage leukemia and sarcoma may represent a heterogeneous, fusion-enriched spectrum that overlaps with, but is not identical to, adult TP53-mutated PEL [9,15,16]. Early CNS and soft-tissue reports highlight NFIA-associated presentations [20,21]. Later reports broaden the marrow-based, CIC-rearranged, and multi-institutional spectrum [22–25], while recent NFIA: CBFA2T3 reports strengthen the molecular subgroup and support cerebrospinal-fluid-based molecular diagnosis [26,27].

Table 2: Reported pediatric acute erythroid leukemia/pure erythroid leukemia and erythroblastic sarcoma cases or series.

Study/ Year	Evidence Type/ Age	Site or Presentation	Erythroid Phenotype	Genetics	Treatment/ Outcome	Main Interpretive Value
Chisholm et al., 2020 [9]	COG pediatric AEL series; 24 cases, including 5 PEL cases	Marrow-based AEL/PEL within pediatric AML trials	Central pathology review with morphologic, immunophenotypic, cytogenetic, molecular, and clinical data	NUP98 fusions in 7/22 molecularly evaluable AEL cases; 3/5 PEL cases had NUP98 fusions; 4/5 PEL cases had complex karyotype	PEL subset had adverse outcome; 5-year OS and EFS each approximately 20%	Largest pediatric cooperative-group dataset; establishes NUP98 enrichment and poor outcome in pediatric PEL
Liu et al., 2020 [15]	Case report; 2-year-old girl	Primary CNS PEL/sarcoma; brain involvement without classic marrow-based presentation	Immature erythroid-lineage neoplasm requiring integrated tissue and molecular work-up	t(1;16)(p31;q24) with NFIA::CBFA2T3; reported cooperating EPOR/JAK2/ ARID1A alterations	AML-type therapy with transplant; alive at reported follow-up	Shows that pediatric PEL/ES may present as isolated CNS disease and that RNA-based fusion testing can be diagnostic
King et al., 2021 [16]	Case report; infant	Extramedullary erythroblastic sarcoma, reported with abdominal involvement	Erythroid sarcoma phenotype in infancy	Novel t(1;8)(p31.3;q21.3) NFIA::RUNX1T1; additional KIT/ARID1A alterations reported in later summaries	Managed using pediatric AML framework	Supports NFIA::RUNX1T1 as an NFIA-fusion analog within pediatric erythroblastic sarcoma
Tauziede-Espariat et al., 2024 [20]	Case report; 3-year-old boy	Isolated CNS erythroblastic sarcoma with seizures and leptomeningeal dissemination	CD45-negative tumor; CD43/CD117 supportive; erythroid markers and fusion result central to diagnosis	NFIA::RUNX1T1 fusion	MyeChild 01-based AML therapy; died within months of presentation	Shows CNS diagnostic mimicry and raises concern for poor outcome in de novo CNS presentations
Anelo et al., 2024 [21]	Case report; 22-month-old girl	Left parotid-region mass with CNS involvement	Highly proliferative erythroid sarcoma; initial histology difficult because of crush/fixation artifact	NFIA::CBFA2T3 detected by clinical RNA sequencing	Chemotherapy reported; alive in summarized follow-up sources	Demonstrates that RNA sequencing may be decisive when morphology and immunohisto-chemistry are inconclusive
Gupta et al., 2025 [22]	Case report; 15-year-old girl	De novo marrow-based AEL with fever, abnormal vaginal bleeding, leukocytosis, severe anemia	PB 87% erythroid cells; marrow 90% erythroid precursors with 60% proerythroblasts; CD71, CD235a, CD36 positive; myeloid markers negative	46,XX,add(4)(p16); ARID1A and ATM variants; no TP53 mutation	7 + 3 AML induction; alive at 3-month post-induction follow-up	Adds a marrow-based adolescent AEL case without TP53 mutation and without the adult-type complex-karyotype paradigm

2026, Vol. 2, Article ID. 2026.0017
https://doi.org/10.69709/CRCT.2026.334455

Table 2: *Cont.*

Study/ Year	Evidence Type/ Age	Site or Presentation	Erythroid Phenotype	Genetics	Treatment/ Outcome	Main Interpretive Value
Cardoni et al., 2025 [23]	Two pediatric ES/PEL cases plus literature review	Pediatric erythroid leukemia/sarcoma with frequent extramedullary presentation	Erythroid-lineage leukemia/sarcoma spectrum	NFIA::CBFA2T3 in both cases; one case also had a TP53 mutation	Case-specific management summarized in review	Strengthens the recurrent NFIA::CBFA2T3/ NFIA::RUNX1T1 fusion-defined pediatric subgroup
Chang-Graham et al., 2025 [24]	Pediatric AEL/erythroblastic sarcoma report	Neonatal/infant presentation; abdominal disease described in later literature summaries	Erythroid-lineage leukemia/sarcoma phenotype	CIC rearrangement, including SREBF1::CIC in summarized sources	Cytarabine-based treatment; poor early outcome in summarized case	Expands pediatric erythroid leukemia/sarcoma genetics beyond NUP98 and NFIA fusions
Fitzpatrick et al., 2025 [25]	Multi-institutional ES series; 56 total ES cases, including pediatric cohort and literature cases	Children showed frequent soft tissue and CNS involvement	CD71 and GLUT1 highly sensitive; E-cadherin and CD117 often supportive; CD45 often absent/weak	Pediatric ES enriched for gene fusions, especially NFIA; adult ES enriched for TP53-mutated disease	Overall prognosis poor; median survival short in combined evaluable cohort	Provides the most substantial comparative dataset to date, while still leaving pediatric prognosis and treatment unresolved
Brunetti et al., 2026 [26]	Case report; 2.5-year-old boy	Extensive extramedullary disease involving mediastinum, gastrointestinal tract, pleura/peritoneum, kidneys, and lymph nodes; minimal marrow involvement	Pleural effusion phenotype CD45-, strong CD117/CD71/CD36/ CD235a, MPO-; marrow showed only a small matching population	NFIA: CBFA2T3 with novel break-point/insertion; no TP53 pathogenic variant reported	AML-like therapy followed by allogeneic HSCT; complete remission 28 months after transplant	Shows disseminated ES with minimal marrow disease and reinforces NFIA: CBFA2T3 as a molecularly defined pediatric entity
Zhao et al., 2026 [27]	Case report and literature review; 1-year-old boy	Diffuse CNS parenchymal infiltration without a discrete mass; diagnosis made from CSF rather than tissue biopsy	CSF flow cytometry showed immature erythroid cells; RNA sequencing established diagnosis	NFIA: CBFA2T3; TP53 mutation and chromosome 17 loss negative; JAK2/EPOR/ARID1A alterations reported	AML-type induction plus azacitidine, venetoclax, intrathecal therapy, and consolida-tion; complete remission at 27 months	Adds a CSF-based diagnostic strategy for critically ill pediatric CNS disease and supports molecular MRD monitoring

2026, Vol. 2, Article ID. 2026.0017
https://doi.org/10.69709/CRCT.2026.334455

5. Morphology and Immunophenotyping

Morphologic assessment begins by determining whether the marrow or tissue is dominated by immature erythroid cells. Proerythroblasts are usually large, with round to irregular nuclei, fine chromatin, prominent nucleoli, deeply basophilic cytoplasm, and frequent cytoplasmic vacuolization. Multinuclearity, nuclear budding, megaloblastoid change, cytoplasmic blebbing, and dyserythropoiesis may be present. The bone marrow is often hypercellular and may show extensive replacement by immature erythroid elements, accompanied by suppression of granulopoiesis and megakaryopoiesis. Auer rods are typically absent, and myeloperoxidase staining is negative in the neoplastic erythroid population. These features are suggestive, but none is sufficiently specific to establish lineage in isolation. Representative bone marrow morphology is shown in Figure 2. Use flow cytometry and immunohistochemistry together. Erythroid precursors are fragile, may be underrepresented following red-cell lysis, and often exhibit weak or absent CD45. CD71 is highly sensitive and typically shows strong expression; however, it is not entirely specific, as transferrin receptor expression may also reflect cellular proliferation [40,41]. E-cadherin is useful for highlighting immature erythroid precursors in marrow biopsy and tissue sections. CD36 supports erythroid differentiation but may also be expressed by monocytes and megakaryocytic cells. Glycophorin A and hemoglobin are more specific markers of erythroid maturation; however, their expression may be weak or absent in highly immature proerythroblastic disease [40]. GLUT1 is a useful adjunctive erythroid marker in tissue sections [42]. Given the overlap between erythroid and megakaryoblastic leukemias, interpretation should remain panel-based rather than dependent on a single marker [43].

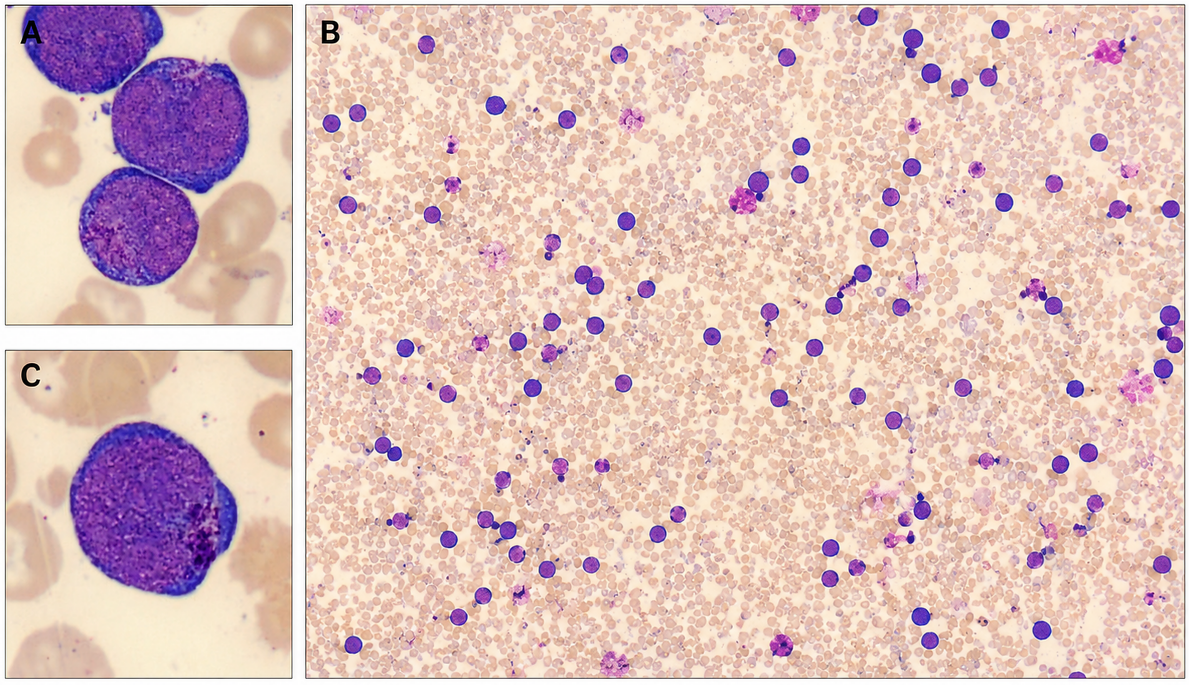

Figure 2: Representative bone marrow aspirate morphology in pediatric pure erythroid leukemia. (**A**,**C**) High-power digital crops show large immature erythroid cells/proerythroblasts with round to slightly irregular nuclei, fine chromatin, prominent nucleoli, deeply basophilic cytoplasm, and cytoplasmic vacuolization. (**B**) Lower-power overview shows numerous dispersed erythroblasts and marked erythroid predominance. The panels comprise anonymized, previously unpublished, patient-derived bone marrow aspirate smear images obtained during routine clinical care and supplied by the authors; they were cropped only for panel assembly. The smears were processed and stained using the Sysmex SP-50 Slidemaker Stainer. Panel (**B**) was examined using a 10× objective, and the digital image was acquired using the CellaVision DC-1 system. Panels (**A**, **C**) were examined using an oil-immersion objective and imaged using the same CellaVision DC-1 system. The exact objective magnification for Panels (**A**, **C**), the specific staining reagent/protocol, and the pixel-to-micrometer calibration could not be independently verified from the available original records. Therefore, no scale bar is provided. Morphologic findings should be interpreted together with the immunophenotypic and molecular findings. Written informed consent for publication of these anonymized images was obtained from the patient's parent/legal guardian; further ethical details are provided in the Ethical Approval and Consent for Publication sections.

2026, Vol. 2, Article ID. 2026.0017
https://doi.org/10.69709/CRCT.2026.334455

CD34 and CD117 require cautious interpretation in suspected pure erythroid leukemia. CD117 may be expressed in a subset of PEL cases, whereas CD34 may be negative, dim, or limited to only a minor population; therefore, absence of CD34 does not exclude acute leukemia, and CD117 positivity alone should not be interpreted as definitive evidence of myeloid lineage [5,8,10,43]. Myeloperoxidase is usually negative in neoplastic erythroid blasts, while megakaryocytic markers, including CD41, CD61, and CD42b, help exclude acute megakaryoblastic leukemia, although aberrant or partial expression must be interpreted within the full morphologic and immunophenotypic context [8,43]. Lymphoid markers should also be included to exclude B- or T-lymphoblastic leukemia, particularly when the abnormal cells exhibit a blastoid morphology and dim CD45 expression. In tissue-based or extramedullary presentations, epithelial, neural, muscle, germ-cell, and other lineage-specific tumor markers may be required to exclude non-hematopoietic small round cell tumors [43]. The diagnosis is strongest when morphology, immunophenotype, and genetic findings are concordant. A marrow replaced by proerythroblasts with strong CD71 and E-cadherin expression, supportive CD36 or GLUT1 staining, negative myeloperoxidase, absence of lineage-defining lymphoid markers, and a clonal cytogenetic or fusion abnormality strongly supports PEL [10,40–43]. By contrast, isolated CD71 positivity is insufficient because CD71 also reflects erythroid proliferation and may be seen in non-neoplastic erythroid expansion [40,41]. Likewise, negativity for glycophorin A does not exclude PEL when the cells are highly immature and other erythroid markers provide convincing evidence of erythroid differentiation [40]. In children, p53 immunohistochemistry should be regarded as supportive rather than obligatory. Abnormal overexpression or a null pattern supports TP53-altered disease, whereas a wild-type pattern should prompt careful evaluation for alternative pediatric drivers, including fusion-defined disease, rather than dismissal of the erythroid diagnosis [13]. Table 3 summarizes the main immunophenotypic markers used in suspected pediatric PEL.

Table 3: Immunophenotypic markers used in suspected pediatric pure erythroid leukemia.

Marker	Typical Interpretation	Main Caveat
CD71	Highly sensitive marker of erythroid precursors.	Not specific; also reflects cellular proliferation.
E-cadherin	Highlights immature erythroid precursors in marrow and tissue.	Best interpreted with a broader erythroid panel.
CD36	Supports erythroid differentiation.	Can also be expressed in monocytes and megakaryocytic cells.
Glycophorin A/hemoglobin	Confirm erythroid maturation when positive.	May be weak or absent in very immature PEL.
GLUT1	Sensitive adjunctive erythroid marker.	Must be interpreted in tissue context.
CD34/CD117	Variable stem/progenitor-associated expression.	Absence of CD34 does not exclude PEL.
MPO, CD41, CD61, CD42b	Help exclude myeloid or megakaryoblastic mimics.	Partial or aberrant expression requires integrated interpretation.

6. Cytogenetic and Molecular Pathophysiology in Pediatric Pure Erythroid Leukemia

Genetics and pathophysiology are difficult to disentangle in PEL because its morphology reflects disrupted erythroid development. Pediatric PEL can be conceptualized as a neoplastic state in which a clone retains erythroid identity, acquires self-renewal capacity, and fails to undergo terminal maturation. Normal erythroid differentiation depends on coordinated transcriptional and chromatin-regulatory networks that progressively establish erythroid identity and maturation [44–46]. Distinct lesions may converge on this phenotype through different roles. NUP98 and NFIA fusions act as transcriptional drivers that impose self-renewal or maturation arrest [9,28,47], while TP53 loss can confer genomic tolerance and a survival advantage [13,14]. EPOR/JAK2 activation often appears to function as a proliferative cooperating pathway, particularly in TP53-altered disease [48]. GATA1s drives trisomy 21-associated myeloid disease, but its main relevance to PEL is as a developmental comparator and diagnostic mimic. Figure 3 summarizes these relationships.

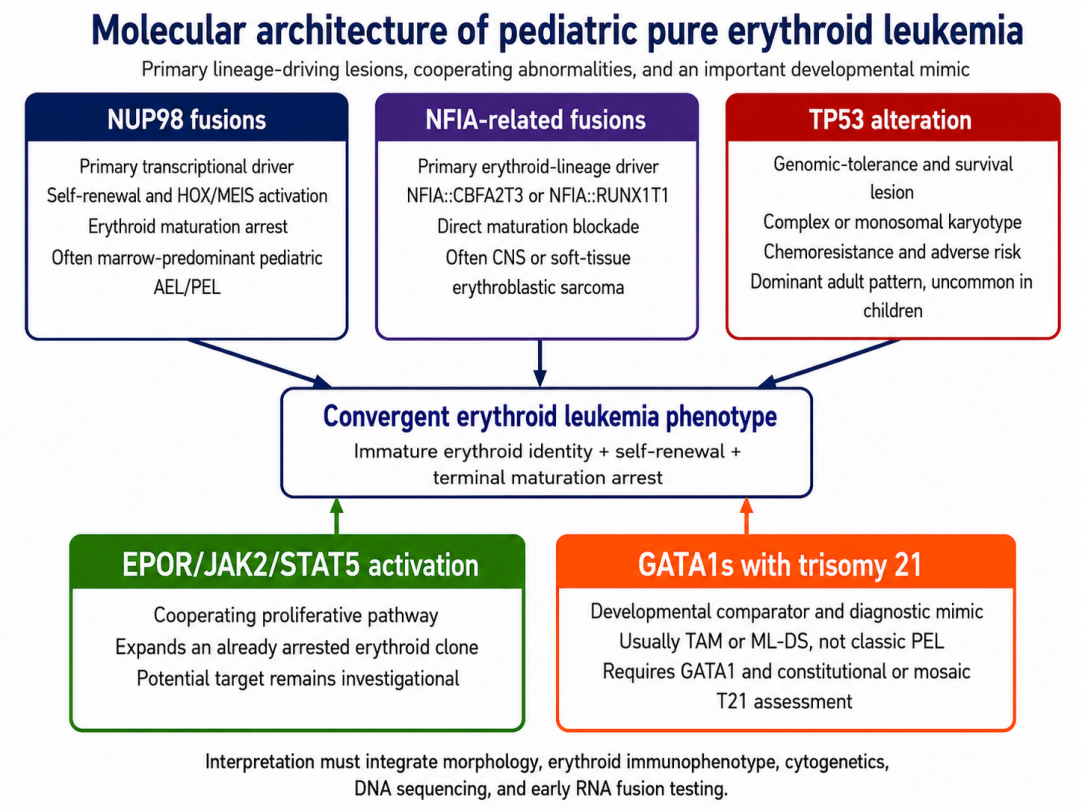

Figure 3: Molecular architecture of pediatric pure erythroid leukemia. Primary lineage-driving lesions, cooperating abnormalities, and the trisomy 21/GATA1s developmental mimic converge on an immature erythroid phenotype through distinct mechanisms.

NUP98 and NFIA fusions are considered primary transcriptional or lineage-driving lesions; TP53 alterations may confer genomic instability and adverse-risk biology; EPOR/JAK2/STAT5 activation may function as a cooperating proliferative pathway; and GATA1s in the setting of trisomy 21 indicates transient abnormal myelopoiesis (TAM) or myeloid leukemia associated with Down syndrome (ML-DS), rather than classic PEL.

TP53-altered PEL remains the best-characterized adult model and should therefore also be evaluated in pediatric populations. Under normal conditions, TP53 regulates the DNA damage response, cell-cycle arrest, cellular senescence, and apoptosis. Adult series link the pure erythroid phenotype to adverse cytogenetics, treatment resistance, and poor outcome [10–12]. Biallelic TP53 loss allows erythroid progenitors with chromosomal damage to evade elimination and survive, creating conditions that promote complex karyotypes, chromosome 5q or 7q losses, and therapy resistance [13,14]. Abnormal p53 immunohistochemistry can help distinguish TP53-altered PEL from reactive erythroid hyperplasia [49]. Mechanistically, TP53 loss may permit damaged erythroid-committed progenitors to proliferate despite failed maturation. Experimental AML data indicate that the antileukemic effect of venetoclax combined with cytarabine and the anthracycline idarubicin is TP53-dependent. These findings support a potential role for TP53 status in determining chemotherapy response but do not establish a PEL-specific or pediatric PEL-specific resistance mechanism [50].

NUP98 fusions offer a pediatric-relevant mechanism of fusion-driven erythroid leukemogenesis. Rearranged NUP98 proteins can alter transcriptional regulation, activate stem-cell and HOX/MEIS-associated programs, maintain chromatin accessibility at self-renewal loci, and impair maturation. In erythroid progenitors, these effects may preserve erythroid identity while preventing normal terminal differentiation. The practical implication is important: NUP98-rearranged pediatric AEL/PEL may be missed if testing relies only on morphology, conventional karyotype, or DNA-only panels. Early RNA-based

2026, Vol. 2, Article ID. 2026.0017
https://doi.org/10.69709/CRCT.2026.334455

fusion testing should therefore be strongly considered in suspicious pediatric cases [9,47,51].

NFIA-related fusions provide one of the clearest mechanisms underlying an erythroid maturation-arrest phenotype. NFIA participates in the transcriptional regulation of erythroid development, whereas CBFA2T3/ETO2 and RUNX1T1/ETO function as transcriptional corepressor partners involved in hematopoietic differentiation. Clinical reports have described: NFIA: CBFA2T3 and NFIA::RUNX1T1 in infant or CNS erythroblastic sarcoma/PEL-like disease [15,16]. Cytogenetic and sequencing studies have also linked CBFA2T3 rearrangements and other rare fusions to acute erythroid leukemia [17–19]. Recent pediatric reports further expand the spectrum of NFIA-associated erythroid tumors [20, 21]. Experimental data show that NFIA-ETO2 blocks erythroid maturation and, with mutant TP53, induces PEL in model systems. These findings support a two-component model in which the fusion establishes an abnormal erythroid transcriptional state and maturation block, while cooperating lesions enhance survival or clonal fitness. Clinically, this helps explain why NFIA-rearranged tumors can present as erythroblastic sarcoma or PEL-like disease with strong erythroid markers, few conventional myeloblasts, and occasional CNS involvement [28].

GATA1 alterations in the context of Down syndrome should be discussed as a distinct developmental pathway rather than as a classic PEL subtype. In constitutional trisomy 21, acquired exon 2 GATA1 mutations generate the short GATA1s isoform and initiate transient abnormal myelopoiesis, while additional cohesin, epigenetic, or signaling lesions can support progression to myeloid leukemia of Down syndrome [30–39]. These disorders typically exhibit megakaryoblastic or mixed megakaryocytic–erythroid differentiation rather than a monomorphic proliferation of proerythroblasts. Their importance in a PEL review is therefore diagnostic: neonates or infants with circulating blasts, nucleated erythroid cells, dyserythropoiesis, CD36 or CD117 expression, or marrow erythroid expansion require assessment for constitutional or mosaic trisomy 21 and GATA1 mutation [30,31,52].

A GATA1s-positive trisomy 21-associated myeloid proliferation should be classified and treated within the TAM or ML-DS framework rather than relabeled as PEL. This distinction differentiates a biologically and therapeutically defined pediatric entity from fusion-driven or TP53-associated erythroid leukemia.

EPOR/JAK2/STAT5 activation and epigenetic dysregulation may function as cooperating mechanisms. Amplification of EPOR and JAK2 can enhance erythropoietin receptor pathway signaling, thereby conferring survival and proliferative advantages on erythroid progenitors [48]. If the same clone harbors a transcriptional lesion that blocks maturation, enhanced signaling may promote expansion of an already arrested erythroid compartment. Similarly, abnormalities in chromatin regulators may stabilize a leukemic erythroid transcriptional program and reduce responsiveness to normal differentiation cues. Integrated genomic studies have identified molecular subgroups of acute erythroid leukemia [47,51], while transcriptomic and model-based work has shown how transcriptional and epigenetic abnormalities can drive disease rather than serve as bystanders [53,54].

Clinical correlations remain provisional because pediatric datasets are small and depend heavily on one cooperative-group reclassification study, small series, and individual reports [9,15,16,20–27]. Limited existing evidence suggests that marrow replacement by immature erythroid cells produces anemia, thrombocytopenia, neutropenia, infection risk, bleeding, and transfusion dependence. In contrast, some fusion-defined pediatric tumors are predominantly extramedullary or CNS-based and have little circulating or marrow disease at presentation. Diagnostic reporting should therefore document karyotype complexity, TP53 mutation and allelic status, copy-number abnormalities, NUP98 or NFIA-related fusions, EPOR/JAK2 pathway alterations, GATA1 mutation when trisomy 21-associated disease is possible, and the method used to detect cryptic rearrangements [1,2,9,10,13, 30,31,48,52]. Table 4 summarizes the genetic lesions and mechanisms that may produce a pediatric pure erythroid leukemia phenotype.

7. Genotype-Phenotype Heterogeneity and Prognostic Stratification

Available pediatric evidence supports several recurring genotype–phenotype patterns; however, these patterns should not be interpreted as validated therapeutic subgroups. TP53-altered, complex-karyotype PEL represents the dominant adult pattern but appears to be uncommon in children. NUP98-rearranged disease is enriched in pediatric AEL and PEL [9], while NFIA-related fusions are repeatedly associated with infants or young children, CNS or soft-tissue erythroblastic sarcoma, and occasionally minimal marrow involvement [15,16,20,21,23,25–27]. Marrow-based pediatric AEL without an identified fusion or TP53 mutation has also been reported [22]. CIC-rearranged and other fusion-defined cases further expand this spectrum, although the available evidence remains limited to isolated cases and small case series [19,24].

Prognostic interpretation should integrate genotype, morphology, disease distribution, and treatment response.

The five PEL cases in the Children's Oncology Group series had 5-year overall and event-free survival of approximately 20%, but the sample was too small for reliable partner-specific analysis [9]. NUP98:: KDM5A was associated with poor outcome in the available pediatric AEL cohort, while NFIA-fusion reports show heterogeneous outcomes ranging from early death to durable remission after AML-directed treatment and, in selected cases, transplantation [9,15,20,26,27]. These data support explicit risk communication but do not justify a definitive pediatric PEL risk score. Table 5 summarizes these genotype-phenotype patterns, the reported treatment responses, and their provisional clinical implications.

Table 4: Genetic lesions and mechanisms that may produce a pediatric pure erythroid leukemia phenotype.

Genetic Lesion or Pathway	Mechanistic Effect	How It Can Generate PEL Biology	Practical Implication
Biallelic TP53 alteration	Loss of DNA-damage checkpoint, apoptosis, and genome surveillance.	Permits expansion of genomically damaged erythroid progenitors with complex karyotype and maturation failure.	Assess TP53 mutation, deletion, VAF, copy-number status, and p53 IHC pattern.
NUP98 fusions	Aberrant transcriptional activation and persistence of stemness programs.	Maintains self-renewal in an immature erythroid progenitor and blocks terminal differentiation.	Use RNA-based fusion testing when pediatric PEL is suspected.
NFIA::CBFA2T3/ NFIA::RUNX1T1	Disruption of erythroid transcriptional regulation and corepressor networks.	Produces an erythroid maturation block and may present as erythroblastic sarcoma/PEL.	Consider in pediatric extramedullary erythroid tumors and CNS disease.
GATA1s with trisomy 21	Altered megakaryocyte-erythroid differentiation in fetal hematopoiesis.	Usually causes TAM/ML-DS rather than classic PEL, but can mimic erythroid leukemia.	Test GATA1 and evaluate constitutional/mosaic trisomy 21 when clinically relevant.
EPOR/JAK2/ STAT5 activation	Enhanced erythroid survival and proliferative signaling.	Expands the arrested erythroid compartment when paired with differentiation blockade.	Look for copy-number gains or pathway activation in comprehensive genomic testing.

8. Differential Diagnosis

The differential diagnosis should begin with non-neoplastic erythroid expansion. Severe vitamin B12 or folate deficiency, copper deficiency, hemolysis, recent bleeding, erythropoietin exposure, marrow recovery after chemotherapy, congenital dyserythropoietic anemia, and viral or inflammatory marrow stress may produce erythroid hyperplasia and dyserythropoiesis. These conditions usually retain a spectrum of erythroid maturation, lack leukemia-defining clonal genetics, and improve when the underlying cause is corrected. Neoplastic mimics include myelodysplastic neoplasm with erythroid predominance, AML with myelodysplasia-related genetics, acute megakaryoblastic leukemia, minimally differentiated AML, acute undifferentiated leukemia, lymphoblastic leukemia or lymphoma, plasma-cell neoplasms, and metastatic pediatric small round-cell tumors. Acute megakaryoblastic leukemia is especially difficult because erythroid and megakaryocytic programs share developmental ancestry, and Down syndrome-associated disease occupies this lineage boundary. A broad panel and genomic testing reduce diagnostic error. PEL should be diagnosed only when an immature erythroid differentiation is convincingly demonstrated and relevant alternative diagnoses have been systematically excluded [5,8,43]. Table 6 summarizes the principal differential diagnoses.

2026, Vol. 2, Article ID. 2026.0017
https://doi.org/10.69709/CRCT.2026.334455

Table 5: Genotype-phenotype patterns, reported treatment response, and provisional clinical implications in pediatric pure erythroid leukemia and erythroblastic sarcoma.

Molecular Pattern	Typical Age or Context	Clinical Distribution	Outcome Signal	Reported Treatment and Response	Clinical Implication	Evidence Strength
Biallelic TP53 alteration with complex or monosomal karyotype	Predominantly adults; uncommon pediatric pattern	Usually marrow-dominant PEL; severe cytopenias; frequent genomic complexity	Extremely poor adult survival; pediatric estimate unavailable	Adult PEL series reported no responses among patients receiving hypomethylating agents, HMA-venetoclax, intensive chemotherapy, or supportive/other therapy; pediatric response data are unavailable [10].	Document allelic status and copy-number loss. Manage within a high-risk AML framework; clinical-trial referral should be considered	Moderate (adult comparative series); Limited (pediatric) [10–14]
NUP98 fusion, including NUP98::KDM5A or NUP98::NSD1	Children and adolescents; partner-specific age variation	Usually marrow AEL/PEL. NUP98::KDM5A often occurs in young children and can show erythroid or megakaryoblastic morphology	High induction MRD and relapse risk in pediatric AML. The PEL subset had poor survival; partner-specific estimates remain unstable	Standard induction response is often poor. A 10-patient pediatric NUP98-rearranged AML cohort reported 20% complete remission after first induction. Selected patients achieved remission with BCL-2-, FLT3-, or CDK6-containing combinations, but the evidence was not PEL-specific [55].	Perform early RNA testing. Apply a high-risk pediatric AML framework and evaluate co-lesions such as FLT3-ITD. Targeted agents remain trial-based	High (cooperative-group cohort) [9]; Limited (treatment response) [55]; Exploratory (targeted therapy) [58,59]
NFIA::CBFA2T3 or NFIA::RUNX1T1	Infants and young children	Often CNS or soft-tissue dominant. In the mixed pediatric erythroblastic sarcoma dataset, CNS and soft-tissue involvement each occurred in 9/20 cases (45%), although this estimate was not NFIA-specific. Marrow involvement may be minimal or delayed	Heterogeneous case outcomes, including early death and durable remission	AML-directed chemotherapy, CNS-directed therapy, and HSCT have produced mixed results, from early death to reported remissions lasting 27 to 28 months in individual cases [15,20,26,27].	Reserve tissue or fluid for RNA sequencing. Complete CNS staging. Consider AML-directed systemic and CNS therapy, with HSCT guided by response and overall risk	Limited (case reports and small series) [15,16,20,21,23,26,27]; Moderate (comparative pathology) [25]; Exploratory (mechanistic) [28]

Table 5: *Cont.*

Molecular Pattern	Typical Age or Context	Clinical Distribution	Outcome Signal	Reported Treatment and Response	Clinical Implication	Evidence Strength
CIC rearrangement or other rare fusion	Neonatal or infant cases reported	Extramedullary or mixed marrow and mass presentation	Poor early outcome reported in isolated cases	Cytarabine-based treatment was followed by poor early outcome in the reported pediatric case. No reproducible subtype-specific response pattern is available [24].	Use broad RNA fusion testing and consider registry enrollment. No subtype-specific regimen has been established	Limited [19,24]
EPOR/JAK2 amplification or activation	Mainly TP53-altered adult AEL or PEL; pediatric frequency uncertain	Marrow-dominant erythroid proliferation with activated STAT5 signaling	Very poor outcome in TP53-altered cohorts	Ruxolitinib activity has been demonstrated in vitro and in xenograft models only; pediatric clinical response data are unavailable [48].	Document the pathway alteration. JAK inhibition should remain limited to a clinical trial or research framework	Moderate (comparative genomic); Exploratory (therapeutic data) [48]
GATA1s with constitutional or mosaic trisomy 21	Neonates and young children with Down syndrome biology	TAM or ML-DS, usually megakaryoblastic or mixed megakaryocytic-erythroid disease	Favorable under ML-DS protocols in many young children; not comparable with PEL	TAM and ML-DS often respond to disease-specific pediatric management, but these treatment outcomes should not be extrapolated to PEL [30–39,52].	Classify as TAM or ML-DS. Use GATA1 and trisomy 21 testing to prevent misdiagnosis	High for TAM/ML-DS (disease-specific evidence; diagnostic mimic, not PEL evidence) [30–39,52]

Evidence strength follows the five-level hierarchy defined in Section 2 and Figure 1 (Highest, High, Moderate, Limited, Exploratory); where a row draws on several evidence types, each component is graded separately.

Table 6: Differential diagnosis of pediatric pure erythroid leukemia.

Entity	Reason for Overlap	Clues Against PEL
Megaloblastic anemia/ reactive erythroid hyperplasia	Erythroid expansion and dyserythropoiesis.	Nutritional or regenerative context; absent clonal leukemia genetics.
MDS with erythroid predominance	Cytopenias, dysplasia, erythroid-rich marrow.	Less monomorphic proerythroblast proliferation; classification depends on blasts and genetics.
Acute megakaryoblastic leukemia	Shared megakaryocyte-erythroid progenitor biology.	Strong CD41/CD61/CD42b or AMKL-defining genetics.
Minimally differentiated AML	MPO-negative immature blasts.	Lacks convincing erythroid marker pattern.
Lymphoblastic lymphoma/ leukemia or sarcoma	Blastoid morphology or mass lesion.	Lineage-defining lymphoid markers or non-hematopoietic tumor profile.

2026, Vol. 2, Article ID. 2026.0017
https://doi.org/10.69709/CRCT.2026.334455

9. Practical Diagnostic Approach

The practical work-up should proceed as an integrated sequence rather than as a descriptive summary. First, establish the clinical trigger and obtain adequate marrow, biopsy, peripheral blood, tissue, and CSF specimens when indicated. Second, determine whether the dominant abnormal population shows immature erythroid morphology with maturation arrest. Third, prove erythroid lineage with a panel that includes sensitive and maturation-associated erythroid markers while actively excluding myeloid, lymphoid, monocytic, megakaryocytic, and non-hematopoietic mimics. Tables 3 and 6 summarize the morphology and immunophenotype criteria.

Genetic testing should proceed in parallel with phenotypic characterization. Conventional karyotype and copy-number assessment identify complex, monosomal, 5q, 7q, 17p, EPOR, or JAK2 abnormalities. DNA-based NGS should include TP53 and relevant myeloid genes, but a negative DNA panel does not exclude fusion-driven PEL. Early RNA-based fusion testing is strongly recommended in suspicious pediatric cases because NUP98, NFIA, CIC, and other rearrangements may be cryptic [9,15–19,24,28]. GATA1 mutation and constitutional or mosaic trisomy 21 assessment should be ordered early when neonatal presentation, Down syndrome, or megakaryocytic-erythroid ambiguity is present [30,31,52]. Tables 4 and 5 summarize the distinction between likely drivers and cooperating lesions, along with provisional genotype-phenotype patterns.

The final report should state the WHO and ICC classification basis; the quantitative and architectural evidence for erythroid predominance; the immunophenotypic evidence for erythroid lineage; the genetic lesion and TP53 allelic status; the marrow and CNS or extramedullary distribution; the major excluded mimics; and the baseline MRD target. Suggested wording is: "acute erythroid leukemia or pure erythroid leukemia, with [genetic abnormality], [TP53 allelic status], and [marrow, CNS, or extramedullary status]." The report should also indicate the strength of evidence supporting unusual fusion-defined interpretations and link the diagnosis to the treatment and MRD frameworks summarized in Tables 7 and 8. Figure 4 integrates the diagnostic, genotypic, treatment, and MRD steps into one workflow.

Table 7: Current treatment framework and evidence limitations in pediatric pure erythroid leukemia.

Clinical Situation	Current Approach	Potential Escalation	Evidence Limitation
Newly diagnosed marrow PEL	Enroll in a pediatric AML protocol or trial. Use protocol-defined intensive induction and response assessment	Risk-adapted consolidation; HSCT assessment for adverse genetics, persistent MRD, or poor response	No PEL-specific prospective trial [9,56]
CNS or extramedullary erythroblastic sarcoma	Systemic AML therapy plus protocol-directed intrathecal treatment. Obtain marrow and complete staging	Individualized HSCT and local control when clinically required	Evidence comes mainly from NFIA-fusion case reports and small series [15,16,20,21,25–27]
NUP98-rearranged disease	Treat as high-risk pediatric AML. Test for cooperating lesions, including FLT3-ITD	Clinical trial for FLT3, menin, BCL-2, or other genotype-directed therapy when appropriate	Targeted evidence is preclinical or small retrospective pediatric AML data, not PEL-specific [55–59]
TP53-altered complex-karyotype disease	High-risk AML management and early clinical-trial referral	HSCT considered only after response and multidisciplinary risk assessment	Adult PEL outcomes are extremely poor; pediatric evidence is sparse [10–14]
EPOR/JAK2-amplified disease	Standard AML treatment while documenting pathway alteration	JAK inhibition only within a clinical trial or exceptional research framework	Ruxolitinib activity is preclinical [48]
Relapsed or refractory disease	Repeat morphology, flow, cytogenetics, DNA and RNA testing; use relapse AML protocol or trial	HSCT or cellular and targeted therapy according to response and availability	No established salvage regimen for pediatric PEL

Table 8: MRD modalities, practical limitations, and proposed use in pediatric pure erythroid leukemia.

Method	Strength	PEL-Specific Limitation	Suggested Use	Evidence
Morphology	Widely available; documents cellular recovery and overt persistence	Low sensitivity; regeneration and dyserythropoiesis can mimic disease; misses isolated CNS or tissue disease	Use with, not instead of, flow or molecular testing	General AML practice; no PEL validation
Multiparameter flow cytometry	Rapid, quantitative, applicable without a known fusion	Fragile erythroblasts, lysis-related cell loss, hemodilution, variable antigen expression, overlap with regenerating erythroid precursors	Record baseline phenotype. Use first-pull marrow, LAIP plus different-from-normal analysis, and a broad exclusion panel	Pediatric AML prognostic evidence; PEL-specific data limited [60,61]
Fusion-specific RT-qPCR or digital PCR	High analytic specificity and sensitivity when the breakpoint is known	Requires a stable, assayable fusion and laboratory validation; partner-specific assays are not universally available	Preferred adjunct for NUP98-, NFIA-, or other fusion-defined disease when technically feasible	Biologically strong; direct pediatric PEL monitoring data are case-based [9,27]
NGS-based MRD	Tracks multiple variants and clonal evolution	Sensitivity and turnaround vary. Persistent mutations may not equal active PEL. RNA fusion detection requires adequate material	Use when validated and when no quantitative PCR assay exists; report limit of detection and target stability	Consensus AML methodology, indirect for PEL [60]
CSF cytology, flow, and molecular testing	Directly assesses documented CNS disease	Low cell count, sample degradation, no standardized PEL threshold, and negative CSF does not exclude parenchymal disease	Use at diagnosis and follow-up in CNS-associated cases according to protocol and clinical status	Limited case evidence [20,27]

10. Treatment and Prognosis

No prospective pediatric PEL trial and no accepted PEL-specific regimen have been reported. Children are generally treated within a contemporary pediatric AML protocol or clinical trial, using protocol-defined cytarabine- and anthracycline-based induction followed by risk-adapted consolidation [9,15,20–27,56]. This approach reflects the lack of an alternative evidence-based standard, not proof that all molecular subtypes respond equally. Reported CNS or other extramedullary cases have generally received systemic AML therapy plus protocol-directed intrathecal treatment. Local radiotherapy or surgery has been used selectively for diagnostic tissue acquisition, neurologic compromise, or local control.

The role of allogeneic hematopoietic stem-cell transplantation (HSCT) after first complete remission remains unresolved for PEL. Current pediatric AML practice uses adverse genetics, induction response, MRD, primary refractory disease, and relapse status to determine transplant eligibility [56,57]. The Children's Oncology Group AEL series was too small to establish a PEL-specific benefit from transplantation, and the reported transplanted patients belonged to the erythroid or myeloid subgroup rather than the five-case PEL subset [9]. Limited case evidence describes durable remission after HSCT in selected NFIA::CBFA2T3-associated disease, but selection and publication bias prevent routine recommendation for every NFIA-fusion case [15,26].

Genotype-directed therapy remains investigational. NUP98-rearranged AML is associated with poor induction response and high MRD, and co-occurring FLT3-ITD should be treated according to pediatric AML protocol or clinical-trial criteria [55,56]. Menin inhibition suppresses NUP98-fusion leukemia in preclinical and patient-derived models, but PEL-specific clinical efficacy remains unestablished [58,59]. A small retrospective pediatric NUP98-rearranged AML study reported responses with combinations containing BCL-2, FLT3, or CDK6 inhibitors, but only 10 NUP98-rearranged patients were included, and the findings do not define a standard regimen [55]. EPOR/JAK2-amplified AEL shows ruxoli-

2026, Vol. 2, Article ID. 2026.0017
https://doi.org/10.69709/CRCT.2026.334455

tinib sensitivity in vitro and in xenograft models, but no validated pediatric clinical strategy exists [48]. Adult TP53-altered PEL generally responds poorly to intensive chemotherapy, hypomethylating agents, and hypomethylating agent–venetoclax combinations; therefore, adult data should not be extrapolated to assume therapeutic benefit in children [10].

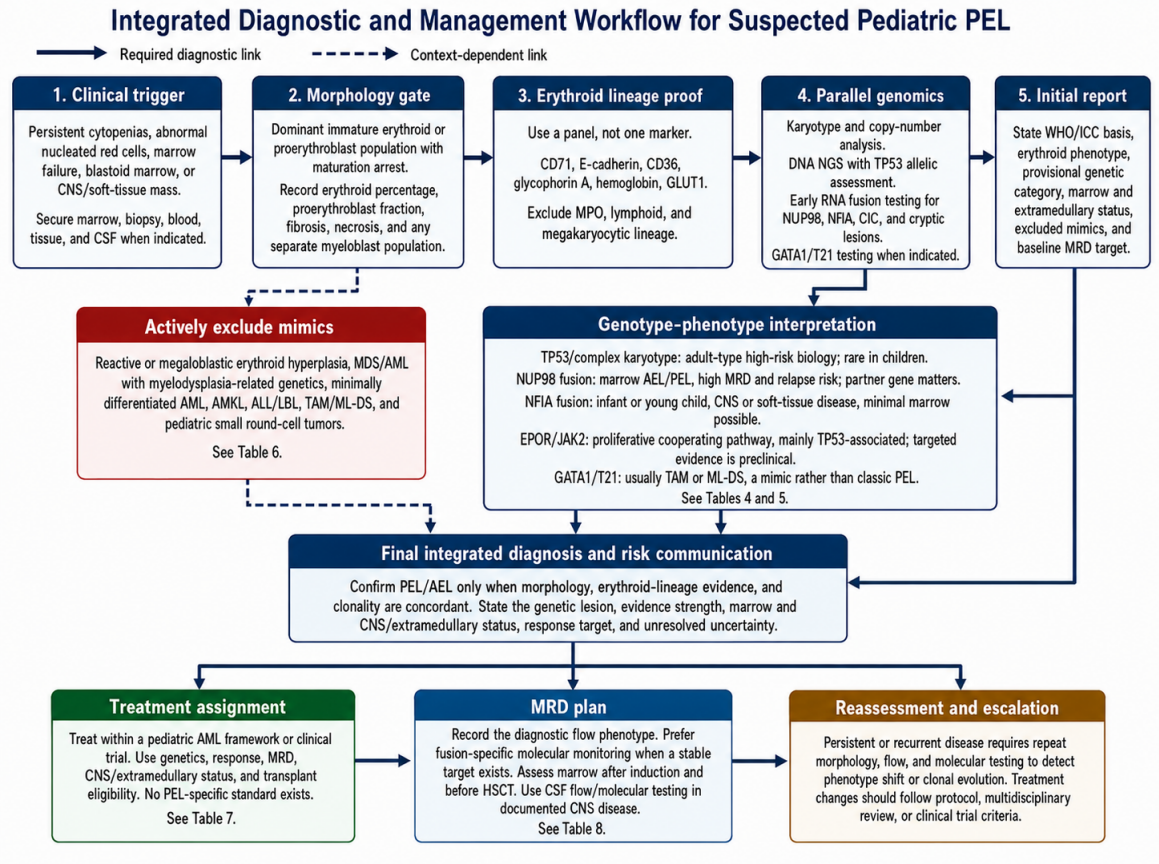

Figure 4: Integrated diagnostic and management workflow for suspected pediatric pure erythroid leukemia. Thick solid arrows indicate required diagnostic links, while dashed arrows indicate context-dependent exclusion or staging steps. The workflow cross-references morphology, molecular subtype, differential diagnosis, treatment, and MRD tables.

Prognosis is generally adverse but heterogeneous. In the largest pediatric cooperative-group analysis, the five patients with PEL had approximately 20% 5-year overall survival and event-free survival [9]. Pediatric erythroblastic sarcoma series also show poor aggregate survival, but mixed adult and pediatric cohorts, variable definitions, and frequent publication of severe extramedullary cases limit direct comparison [25]. Potential adverse features include PEL morphology, complex or monosomal karyotype, biallelic TP53 alteration, NUP98::KDM5A, induction failure, persistent MRD, relapse, and disseminated CNS or soft-tissue disease. These features should guide risk communication and trial referral, but they do not yet constitute a validated pediatric PEL prognostic model.

11. Measurable Residual Disease Monitoring

MRD is a central prognostic tool in pediatric AML; however, no PEL-specific threshold or validated MRD assay has been established [60,61]. Morphology alone is inadequate because its conventional detection limit is approximately 5%, early erythroid regeneration can mimic residual disease, and PEL may persist in extramedullary sites despite a morphologically negative marrow. Morphology should therefore describe response and marrow recovery but should not serve as the sole MRD method.

Multiparameter flow cytometry should use the diagnostic sample to define a leukemia-associated immunophenotype and should also apply a different-from-normal strategy at follow-up [60,61]. A PEL-oriented

panel can include CD71, CD36, CD117, CD34, CD45, glycophorin A or another erythroid marker suitable for flow, and exclusion markers for myeloid, lymphoid, monocytic, and megakaryocytic differentiation. Practical limitations include erythroblast fragility, cell loss during red-cell lysis, hemodilution, variable CD34 or CD117 expression, and phenotypic shifts after treatment. Reserve the first marrow pull for MRD when feasible, and interpret flow results alongside biopsy findings and regeneration status.

Molecular MRD is potentially more specific in fusion-defined pediatric disease. When the genomic breakpoint is known, patient-specific RT-qPCR, digital PCR, or validated RNA- or DNA-based sequencing can track NUP98, NFIA, or another stable fusion. A negative broad DNA panel at diagnosis does not provide a molecular MRD target, and a mutation such as TP53 should be interpreted with allelic context and paired with flow because persistence may not always represent the same active leukemic population. The laboratory report should state assay sensitivity, specimen type, target stability, and the quantitative reporting threshold [60].

For documented CNS disease, CSF cytology should be combined with flow cytometry and, when technically validated, fusion-specific molecular testing. Reported use of CSF flow and NFIA::CBFA2T3 RNA detection shows diagnostic and monitoring feasibility, but current evidence is limited to individual cases, and no standardized CSF MRD threshold or schedule exists [27]. Reasonable AML-based time points include diagnosis, the end of induction courses, pre-HSCT assessment, post-HSCT surveillance when a stable molecular target exists, and any clinical suspicion of relapse. Treatment adjustment should follow the applicable pediatric AML protocol or multidisciplinary trial criteria rather than an unvalidated PEL-specific MRD cutoff.

12. Critical Appraisal and Evidence Gaps

The evidence base has major structural limitations. The largest pediatric study included only five cases of PEL, while most observations involving NFIA-, CIC-, and other fusion-defined subgroups derive from individual case reports or small case series [9,15,16,20–27]. Classification changes from FAB AML-M6 through successive WHO and ICC systems create substantial case-mixing and prevent direct comparison of older survival data. Publication bias likely favors unusual extramedullary presentations, molecularly solved cases, and severe outcomes. Conversely, children who respond well without extensive molecular testing may be underrepresented. The structured database search was limited to PubMed, supplemented by backward and forward citation screening and targeted journal-website searches; no other bibliographic databases were searched, and only English-language full-text publications were included. Studies indexed only in other databases, non-English reports, and grey literature may therefore have been missed. Initial database retrieval and exclusion counts were not prospectively archived. Figure 1 therefore represents a reconstructed audit of the final deduplicated source library rather than a prospectively documented PRISMA flow diagram.

Treatment and MRD conclusions require similar caution. No randomized or prospective PEL-specific therapeutic trial has been reported, HSCT selection is confounded by response and genetic risk, and targeted-therapy evidence is largely preclinical or derived from broader NUP98-rearranged pediatric AML [48,55–59]. Flow-cytometric and molecular MRD methods have not been specifically validated for detecting fragile erythroid blasts or CNS erythroblastic sarcoma. Future progress requires international registry-based case capture, harmonized WHO and ICC annotation, central morphologic and immunophenotypic review, paired DNA and RNA sequencing, standardized marrow and CSF MRD collection, and prospective reporting of treatment exposure and outcome.

13. Conclusions

Pediatric PEL is a rare, high-risk erythroid-lineage leukemia that requires an integrated diagnostic approach and careful exclusion of reactive erythroid hyperplasia, myelodysplastic neoplasms, AML with myelodysplasia-related genetics, acute megakaryoblastic leukemia, and Down syndrome-associated myeloid proliferations. The adult model of biallelic TP53 alteration and complex karyotype remains important, but childhood disease includes NUP98-, NFIA-, CIC-, and other fusion-defined presentations with distinct marrow and extramedullary patterns. No PEL-specific pediatric treatment standard or validated prognostic score exists. Current management should follow a high-quality pediatric AML protocol or clinical trial, with HSCT decisions based on genetics, treatment response, MRD, relapse status, and disease distribution. MRD should combine flow cytometry with fusion-specific molecular monitoring when available, while CSF-based monitoring remains case-supported and unstandardized. Immediate priorities include transparent evidence grading, early RNA fusion testing, genotype-aware reporting, harmonized MRD methods, and international prospective registration.

2026, Vol. 2, Article ID. 2026.0017
https://doi.org/10.69709/CRCT.2026.334455

List of Abbreviations

AEL	Acute Erythroid Leukemia
AI	Artificial Intelligence
AMKL	Acute Megakaryoblastic Leukemia
AML	Acute Myeloid Leukemia
AML-M6	Acute Myeloid Leukemia M6
ARID1A	AT-Rich Interaction Domain 1A
ATM	Ataxia Telangiectasia Mutated
BCL-2	B-Cell Lymphoma 2
CBFA2T3	CBFA2/RUNX1 Partner Transcriptional Co-repressor 3
CDK6	Cyclin-Dependent Kinase 6
CIC	Capicua Transcriptional Repressor
CNS	Central Nervous System
COG	Children's Oncology Group
CSF	Cerebrospinal Fluid
DNA	Deoxyribonucleic Acid
EFS	Event-Free Survival
EPOR	Erythropoietin Receptor
ES	Erythroblastic Sarcoma
FAB	French–American–British
FISH	Fluorescence In Situ Hybridization
FLT3	FMS-Like Tyrosine Kinase 3
GATA1	GATA Binding Protein 1
GATA1s	Short Isoform of GATA1
GLUT1	Glucose Transporter 1
HMA	Hypomethylating Agent
HOX/MEIS	Homeobox And Myeloid Ecotropic Viral Integration Site Transcriptional Programs
HSCT	Hematopoietic Stem-Cell Transplantation
ICC	International Consensus Classification
IHC	Immunohistochemistry
JAK2	Janus Kinase 2
KIT	KIT Proto-Oncogene Receptor Tyrosine Kinase
LAIP	Leukemia-Associated Immunophenotype
MDS	Myelodysplastic Neoplasms
MEDLINE	Medical Literature Analysis and Retrieval System Online
ML-DS	Myeloid Leukemia of Down syndrome
MPO	Myeloperoxidase
MRD	Measurable Residual Disease
NFIA	Nuclear Factor I A
NGS	Next-Generation Sequencing
NUP98	Nucleoporin 98
OS	Overall Survival
PB	Peripheral Blood
PEL	Pure Erythroid Leukemia
RNA	Ribonucleic Acid
RT-qPCR	Reverse-Transcription Quantitative Polymerase Chain Reaction
RUNX1T1	RUNX1 Partner Transcriptional Co-Repressor 1
SANRA	Scale For the Assessment of Narrative Review Articles
SREBF1	Sterol Regulatory Element-Binding Transcription Factor 1
STAT5	Signal Transducer and Activator of Transcription 5
TAM	Transient Abnormal Myelopoiesis
TP53	Tumor Protein P53
VAF	Variant Allele Frequency
WHO	World Health Organization

Author Contributions

Conceptualization, methodology, investigation, data curation, visualization, project administration, and writing—original draft: Y.Y.; Validation, formal analysis, and supervision: R.P.; Writing—review and editing: Y.Y. and R.P. All authors have read and agreed to the published version of the manuscript.

Availability of Data and Materials

All literature-derived data discussed in this narrative review are available in the cited publications. Figure 2 comprises original, previously unpublished, anonymized patient-derived bone marrow aspirate images supplied by the authors; these images are not available in the cited literature. The original source image files are retained for editorial verification and are not publicly deposited because they derive from clinical material and remain subject to applicable ethical and privacy restrictions. The source files may be provided confidentially to the editorial office by the corresponding author upon request.

Ethics Committee Approval

This narrative review did not involve prospective human-subject research or collection of new research data. Figure 2 comprises anonymized, previously unpublished bone marrow aspirate images obtained during routine clinical care and supplied by the authors. No additional research procedure was performed for the purposes of this review. The ethical basis for publication of these clinical images is the written informed consent for publication obtained from the patient's parent/legal guardian, as stated below.

Consent for Publication

Figure 2 contains anonymized, previously unpublished patient-derived bone marrow aspirate images obtained during routine clinical care and supplied by the authors. The images contain no directly identifying patient infor-

mation. The patient's parent/legal guardian provided written informed consent for publication of the anonymized clinical images.

Conflicts of Interest

The authors declare no conflicts of interest.

Funding

The study did not receive any external funding and was conducted using only institutional resources.

Acknowledgments

None declared.

AI Declaration

The use of artificial intelligence (AI) tools was limited to editorial and organizational assistance. ChatGPT (OpenAI) assisted with language polishing, response organization, and preliminary layout planning. Google NotebookLM assisted with organization of author-selected source materials and preliminary visual planning. No AI tool generated original research data, performed independent literature selection, interpreted patient findings, or produced unsupported scientific or clinical recommendations. The authors manually reviewed and verified every statement, reference, table, and figure and take full responsibility for the integrity, accuracy, and final content of the work.

References

[1] Khoury, J.D.; Solary, E.; Abla, O.; Akkari, Y.; Alaggio, R.; Apperley, J.F.; Bejar, R.; Berti, E.; Busque, L.; Chan, J.K.C.; et al. The 5th Edition of the World Health Organization Classification of Haematolymphoid Tumours: Myeloid and Histiocytic/Dendritic Neoplasms. *Leukemia* **2022**, *36*(7), 1703–1719. [CrossRef] [PubMed]

[2] Arber, D.A.; Orazi, A.; Hasserjian, R.P.; Borowitz, M.J.; Calvo, K.R.; Kvasnicka, H.-M.; Wang, S.A.; Bagg, A.; Barbui, T.; Branford, S.; et al. International Consensus Classification of Myeloid Neoplasms and Acute Leukemias Integrating Morphologic, Clinical, and Genomic Data. *Blood* **2022**, *140*(11), 1200–1228. [CrossRef] [PubMed]

[3] Arber, D.A.; Orazi, A.; Hasserjian, R.; Thiele, J.; Borowitz, M.J.; Le Beau, M.M.; Bloomfield, C.D.; Cazzola, M.; Vardiman, J.W. The 2016 Revision to the World Health Organization Classification of Myeloid Neoplasms and Acute Leukemia. *Blood* **2016**, *127*(20), 2391–2405. [CrossRef] [PubMed]

[4] Vardiman, J.W.; Thiele, J.; Arber, D.A.; Brunning, R.D.; Borowitz, M.J.; Porwit, A.; Harris, N.L.; Le Beau, M.M.; Hellstrom-Lindberg, E.; Tefferi, A.; et al. The 2008 Revision of the World Health Organization (WHO) Classification of Myeloid Neoplasms and Acute Leukemia: Rationale and Important Changes. *Blood* **2009**, *114*(5), 937–951. [CrossRef] [PubMed]

[5] Wang, W.; Wang, S.A.; Medeiros, L.J.; Khoury, J.D. Pure Erythroid Leukemia. *Am. J. Hematol.* **2017**, *92*(3), 292–296. [CrossRef] [PubMed]

[6] Alexander, C. A History and Current Understanding of Acute Erythroid Leukemia. *Clin. Lymphoma Myeloma Leuk.* **2023**, *23*(8), 583–588. [CrossRef] [PubMed]

[7] Fernandes, P.; Waldron, N.; Chatzilygeroudi, T.; Naji, N.S.; Karantanos, T. Acute Erythroid Leukemia: From Molecular Biology to Clinical Outcomes. *Int. J. Mol. Sci.* **2024**, *25*(11), 6256. [CrossRef] [PubMed]

[8] Zuo, Z.; Polski, J.M.; Kasyan, A.; Medeiros, L.J. Acute Erythroid Leukemia. *Arch. Pathol. Lab. Med.* **2010**, *134*(9), 1261–1270. [CrossRef] [PubMed]

[9] Chisholm, K.M.; Heerema-McKenney, A.E.; Choi, J.K.; Smith, J.; Ries, R.E.; Hirsch, B.A.; Raimondi, S.C.; Alonzo, T.A.; Wang, Y.-C.; Aplenc, R.; et al. Acute Erythroid Leukemia Is Enriched in NUP98 Fusions: A Report from the Children's Oncology Group. *Blood Adv.* **2020**, *4*(23), 6000–6008. [CrossRef] [PubMed]

[10] Reichard, K.K.; Tefferi, A.; Abdelmagid, M.; Orazi, A.; Alexandres, C.; Haack, J.; Greipp, P.T. Pure (Acute) Erythroid Leukemia: Morphology, Immunophenotype, Cytogenetics, Mutations, Treatment Details, and Survival Data among 41 Mayo Clinic Cases. *Blood Cancer J.* **2022**, *12*(11), 147. [CrossRef] [PubMed]

[11] Hasserjian, R.P.; Zuo, Z.; Garcia, C.; Tang, G.; Kasyan, A.; Luthra, R.; Abruzzo, L.V.; Kantarjian, H.M.; Medeiros, L.J.; Wang, S.A. Acute Erythroid Leukemia: A Reassessment Using Criteria Refined in the 2008 WHO Classification. *Blood* **2010**, *115*(10), 1985–1992. [CrossRef] [PubMed]

[12] Liu, W.; Hasserjian, R.P.; Hu, Y.; Zhang, L.; Miranda, R.N.; Medeiros, L.J.; Wang, S.A. Pure Erythroid Leukemia: A Reassessment of the Entity Using the 2008 World Health Organization Classification. *Mod. Pathol.* **2011**, *24*(3), 375–383. [CrossRef] [PubMed]

[13] Fang, H.; Wang, S.A.; Khoury, J.D.; El Hussein, S.; Kim, D.H.; Tashakori, M.; Tang, Z.; Li, S.; Hu, Z.; Jelloul, F.Z.; et al. Pure erythroid leukemia is characterized by biallelic TP53 inactivation and abnormal p53 expression patterns in *de novo* and secondary cases. *Haematologica* **2022**, *107*(9), 2232–2237. [CrossRef] [PubMed]

[14] Grossmann, V.; Bacher, U.; Haferlach, C.; Schnittger, S.; Potzinger, F.; Weissmann, S.; Roller, A.; Eder, C.; Fasan, A.; Zenger, M.; et al. Acute Erythroid Leukemia (AEL) Can Be Separated into Distinct Prognostic Subsets Based on Cytogenetic and Molecular Genetic Characteristics. *Leukemia* **2013**, *27*(9), 1940–1943. [CrossRef] [PubMed]

[15] Liu, H.; Guinipero, T.L.; Schieffer, K.M.; Carter, C.; Colace, S.; Leonard, J.R.; Orr, B.A.; Kah-

wash, S.B.; Brennan, P.J.; Fitch, J.R.; et al. De Novo Primary Central Nervous System Pure Erythroid Leukemia/Sarcoma with t(1;16)(p31;q24) NFIA/CBFA2T3 Translocation. *Haematologica* **2020**, *105*(4), 194–197. [CrossRef] [PubMed]

[16] King, R.L.; Siaghani, P.J.; Wong, K.; Edlefsen, K.; Shane, L.; Howard, M.T.; Reichard, K.K.; Mai, M.; Viswanatha, D.S.; Greipp, P.T.; et al. Novel t(1;8)(p31.3;q21.3) NFIA-RUNX1T1 Translocation in an Infant Erythroblastic Sarcoma: Building a Case for a Rare Genetically Defined Entity. *Am. J. Clin. Pathol.* **2021**, *156*(1), 129–138. [CrossRef] [PubMed]

[17] Micci, F.; Thorsen, J.; Haugom, L.; Zeller, B.; Tierens, A.; Heim, S. Translocation t(1;16)(p31;q24) Rearranging CBFA2T3 Is Specific for Acute Erythroid Leukemia. *Leukemia* **2011**, *25*(9), 1510–1512. [CrossRef] [PubMed]

[18] Micci, F.; Thorsen, J.; Panagopoulos, I.; Nyquist, K.B.; Zeller, B.; Tierens, A.; Heim, S. High-throughput sequencing identifies an NFIA/CBFA2T3 fusion gene in acute erythroid leukemia with t(1;16)(p31;q24). *Leukemia* **2013**, *27*(4), 980–982. [CrossRef] [PubMed]

[19] Panagopoulos, I.; Micci, F.; Thorsen, J.; Haugom, L.; Buechner, J.; Kerndrup, G.; Tierens, A.; Zeller, B.; Heim, S. Fusion of ZMYND8 and RELA Genes in Acute Erythroid Leukemia. *PLoS ONE* **2013**, *8*(5), e63663. [CrossRef] [PubMed]

[20] Tauziede-Espariat, A.; Lew-Derivry, L.; Abbou, S.; Métais, A.; Pierron, G.; Reynaud, S.; Masliah-Planchon, J.; Mariet, C.; Hasty, L.; Dangouloff-Ros, V.; et al. CNS Erythroblastic Sarcoma: A Potential Emerging Pediatric Tumor Type Characterized by NFIA::RUNX1T1/3 Fusions. *Acta Neuropathol. Commun.* **2024**, *12*(1), 12. [CrossRef] [PubMed]

[21] Anelo, O.M.; Ma, J.; Neary, J.L.; Koo, S.C.; Inaba, H.; Pinto, S.N.; Nguyen, N.T.; Hoang, T.N.; Bui, L.N.; Klco, J.M.; et al. Pediatric Erythroid Sarcoma Diagnostically Confirmed by Identification of a Recurrent NFIA::CBFA2T3 Fusion. *Genes Chromosom. Cancer* **2024**, *63*(6), e23251. [CrossRef] [PubMed]

[22] Gupta, L.; Gajendra, S.; Jha, A.K.; Talasila, N.B.K. Acute Erythroid Leukemia in a Child: Insights from a Rare Case. *Am. J. Blood Res.* **2025**, *15*(4), 96–101. [CrossRef] [PubMed]

[23] Cardoni, A.; Rogges, E.; Rossi, S.; De Vito, R.; Rullo, E.; Vallese, S.; Barresi, S.; Giovannoni, I.; Tancredi, C.; Alesi, V.; et al. Pediatric Erythroblastic Sarcoma/Pure Erythroid Leukemia with NFIA-CBFA2T3 Translocation: Report of Two Cases, Including a Case with TP53 Mutation, and Review of the Literature. *Hum. Pathol. Rep.* **2025**, *42*, 300803. [CrossRef]

[24] Chang-Graham, A.L.; Nguyen, T.; Oak, J.; Silva, O.; Gruber, T.A. CIC-Rearrangements in Pediatric Acute Erythroid Leukemia/Erythroblastic Sarcoma. *Pediatr. Blood Cancer* **2025**, *72*(9), e31848. [CrossRef] [PubMed]

[25] Fitzpatrick, M.J.; Yuan, J.; Capa, I.; Bledsoe, J.R.; Kibler, C.E.; Tucker, C.; Shuai, W.; Matsumoto, N.P.; Zhu, G.G.; Ding, Y.; et al. Erythroblastic Sarcoma in Adults and Children: Different Pathways to the Same Destination. *Mod. Pathol.* **2025**, *38*(8), 100716. [CrossRef] [PubMed]

[26] Brunetti, M.; Andersen, K.; Tjønnfjord, G.E.; Zeller, B.; Spetalen, S.; Munthe-Kaas, M.C.; Osnes, L.T.N.; Os, T.T.; Micci, F. The NFIA::CBFA2T3 Identifies a Molecularly Defined Subgroup of Acute Erythroid Leukemia/Erythroid Sarcoma. *Front. Oncol.* **2026**, *16*, 1809156. [CrossRef] [PubMed]

[27] Zhao, Y.; Huang, Z.; Xue, L.; Zhang, L.; Jia, Y. Identification of an NFIA::CBFA2T3 Fusion in Cerebrospinal Fluid Confirms the Diagnosis of Pediatric CNS Myeloid Sarcoma with Erythroid Differentiation: A Case Report and Literature Review. *Front. Oncol.* **2026**, *16*, 1676730. [CrossRef] [PubMed]

[28] Piqué-Borràs, M.-R.; Jevtic, Z.; Bagger, F.O.; Seguin, J.; Sivalingam, R.; Bezerra, M.F.; Louwaige, A.; Juge, S.; Nellas, L.; Ivanek, R.; et al. The NFIA-ETO2 Fusion Blocks Erythroid Maturation and Induces Pure Erythroid Leukemia in Cooperation with Mutant TP53. *Blood* **2023**, *141*(18), 2245–2260. [CrossRef] [PubMed]

[29] Baethge, C.; Goldbeck-Wood, S.; Mertens, S. SANRA—A Scale for the Quality Assessment of Narrative Review Articles. *Res. Integr. Peer Rev.* **2019**, *4*, 5. [CrossRef] [PubMed]

[30] Wechsler, J.; Greene, M.E.; McDevitt, M.A.; Anastasi, J.; Karp, J.E.; Le Beau, M.M.; Crispino, J. Acquired Mutations in GATA1 in the Megakaryoblastic Leukemia of Down Syndrome. *Nat. Genet.* **2002**, *32*(1), 148–152. [CrossRef] [PubMed]

[31] Xu, G.; Nagano, M.; Kanezaki, R.; Toki, T.; Hayashi, Y.; Taketani, T.; Taki, T.; Mitui, T.; Koike, K.; Kato, K.; et al. Frequent mutations in the GATA-1 gene in the transient myeloproliferative disorder of Down syndrome. *Blood* **2003**, *102*(8), 2960–2968. [CrossRef] [PubMed]

[32] Kanezaki, R.; Toki, T.; Terui, K.; Xu, G.; Wang, R.; Shimada, A.; Hama, A.; Kanegane, H.; Kawakami, K.; Endo, M.; et al. Down Syndrome and GATA1 Mutations in Transient Abnormal Myeloproliferative Disorder: Mutation Classes Correlate with Progression to Myeloid Leukemia. *Blood* **2010**, *116*(22), 4631–4638. [CrossRef] [PubMed]

[33] Alford, K.A.; Reinhardt, K.; Garnett, C.; Norton, A.; Böhmer, K.; von Neuhoff, C.; Kolenova, A.; Marchi, E.; Klusmann, J.-H.; Roberts, I.; et al. Analysis of GATA1 Mutations in Down Syndrome Transient Myeloproliferative Disorder and Myeloid Leukemia. *Blood* **2011**, *118*(8), 2222–2238. [CrossRef] [PubMed]

[34] Bhatnagar, N.; Nizery, L.; Tunstall, O.; Vyas, P.; Roberts, I. Transient Abnormal Myelopoiesis and AML in Down Syndrome: An Update. *Curr. Hematol. Malig. Rep.* **2016**, *11*(5), 333–341. [CrossRef] [PubMed]

[35] Roberts, I.; Izraeli, S. Haematopoietic Development and Leukaemia in Down Syndrome. *Br. J. Haematol.* **2014**, *167*(5), 587–599. [CrossRef] [PubMed]

[36] Hasle, H.; Clemmensen, I.H.; Mikkelsen, M. Risks of Leukaemia and Solid Tumours in Individuals with Down's Syndrome. *Lancet* **2000**, *355*(9199), 165–169. [CrossRef] [PubMed]

[37] Nikolaev, S.I.; Santoni, F.; Vannier, A.; Falconnet, E.; Giarin, E.; Basso, G.; Hoischen, A.; Veltman, J.A.; Groet, J.; Nizetic, D.; et al. Exome Sequencing Identifies Putative Drivers of Progression of Transient Myeloproliferative Disorder to AMKL in Infants with Down Syndrome. *Blood* **2013**, *122*(4), 554–561. [CrossRef] [PubMed]

[38] Yoshida, K.; Toki, T.; Okuno, Y.; Kanezaki, R.; Shiraishi, Y.; Sato-Otsubo, A.; Sanada, M.; Park, M.-J.; Terui, K.; Suzuki, H.; et al. The Landscape of Somatic Mutations in Down Syndrome-Related Myeloid Disorders. *Nat. Genet.* **2013**, *45*(11), 1293–1299. [CrossRef] [PubMed]

[39] Terui, K.; Toki, T.; Taga, T.; Iwamoto, S.; Miyamura, T.; Hasegawa, D.; Moritake, H.; Hama, A.; Nakashima, K.; Kanezaki, R.; et al. Highly Sensitive Detection of GATA1 Mutations in Patients with Myeloid Leukemia Associated with Down Syndrome by Combining Sanger and Targeted Next Generation Sequencing. *Genes Chromosom. Cancer* **2020**, *59*(3), 160–167. [CrossRef] [PubMed]

[40] Dong, H.Y.; Wilkes, S.; Yang, H. CD71 Is Selectively and Ubiquitously Expressed at High Levels in Erythroid Precursors of All Maturation Stages: A Comparative Immunochemical Study with Glycophorin A and Hemoglobin A. *Am. J. Surg. Pathol.* **2011**, *35*(5), 723–732. [CrossRef] [PubMed]

[41] Acharya, S.; Sharma Kala, P. Role of CD71 in Acute Leukemia: An Immunophenotypic Marker for Erythroid Lineage or Proliferation? *Indian J. Pathol. Microbiol.* **2019**, *62*(3), 418–422. [PubMed]

[42] Kaumeyer, B.A.; Fidai, S.S.; Thakral, B.; Wang, S.A.; Arber, D.A.; Cheng, J.X.; Gurbuxani, S.; Venkataraman, G. GLUT1 Immunohistochemistry Is a Highly Sensitive and Relatively Specific Marker for Erythroid Lineage in Benign and Malignant Hematopoietic Tissues. *Am. J. Clin. Pathol.* **2022**, *158*(2), 228–234. [CrossRef] [PubMed]

[43] Wang, S.A.; Hasserjian, R.P. Acute Erythroleukemias, Acute Megakaryoblastic Leukemias, and Reactive Mimics: A Guide to a Number of Perplexing Entities. *Am. J. Clin. Pathol.* **2015**, *144*(1), 44–60. [CrossRef] [PubMed]

[44] Cantor, A.B.; Orkin, S.H. Transcriptional Regulation of Erythropoiesis: An Affair Involving Multiple Partners. *Oncogene* **2002**, *21*(21), 3368–3376. [CrossRef] [PubMed]

[45] Kerenyi, M.A.; Orkin, S.H. Networking Erythropoiesis. *J. Exp. Med.* **2010**, *207*(12), 2537–2541. [CrossRef] [PubMed]

[46] Hattangadi, S.M.; Wong, P.; Zhang, L.; Flygare, J.; Lodish, H.F. From Stem Cell to Red Cell: Regulation of Erythropoiesis at Multiple Levels by Multiple Proteins, RNAs, and Chromatin Modifications. *Blood* **2011**, *118*(24), 6258–6268. [CrossRef] [PubMed]

[47] Iacobucci, L.; Wen, J.; Meggendorfer, M.; Choi, J.K.; Shi, L.; Pounds, S.B.; Carmichael, C.L.; Masih, K.E.; Morris, S.M.; Lindsley, R.C.; et al. Genomic Subtyping and Therapeutic Targeting of Acute Erythroleukemia. *Nat. Genet.* **2019**, *51*(4), 694–704. [CrossRef] [PubMed]

[48] Takeda, J.; Yoshida, K.; Nakagawa, M.M.; Nannya, Y.; Yoda, A.; Saiki, R.; Ochi, Y.; Zhao, L.; Okuda, R.; Qi, X.; et al. Amplified EPOR/JAK2 Genes Define a Unique Subtype of Acute Erythroid Leukemia. *Blood Cancer Discov.* **2022**, *3*(5), 410–427. [CrossRef] [PubMed]

[49] Alexandres, C.; Basha, B.; King, R.L.; Howard, M.T.; Reichard, K.K. p53 Immunohistochemistry Discriminates between Pure Erythroid Leukemia and Reactive Erythroid Hyperplasia. *J. Hematop.* **2021**, *14*, 15–22. [CrossRef]

[50] Teh, T.-C.; Nguyen, N.-Y.; Moujalled, D.M.; Segal, D.; Pomilio, G.; Rijal, S.; Jabbour, A.; Cummins, K.; Lackovic, K.; Blombery, P.; et al. Enhancing Venetoclax Activity in Acute Myeloid Leukemia by Co-Targeting MCL1. *Leukemia* **2018**, *32*(2), 303–312. [CrossRef] [PubMed]

[51] Iacobucci, I.; Qu, C.; Varotto, E.; Janke, L.J.; Yang, X.; Seth, A.; Shelat, A.; Friske, J.D.; Fukano, R.; Yu, J.; et al. Modeling and Targeting of Erythroleukemia by Hematopoietic Genome Editing. *Blood* **2021**, *137*(12), 1628–1640. [CrossRef] [PubMed]

[52] Tunstall, O.; Bhatnagar, N.; James, B.; Norton, A.; O'Marcaigh, A.S.; Watts, T.; Greenough, A.; Vyas, P.; Roberts, I.; Wright, M.; et al. Guidelines for the Investigation and Management of Transient Leukaemia of Down Syndrome. *Br. J. Haematol.* **2018**, *182*(2), 200–211. [CrossRef] [PubMed]

[53] Fagnan, A.; Bagger, F.O.; Piqué-Borras, M.-R.; Ignacimouttou, C.; Caulier, A.; Lopez, C.K.; Robert, E.; Uzan, B.; Gelsi-Boyer, V.; Aid, Z.; et al. Human Erythroleukemia Genetics and Transcriptomes Identify Master Transcription Factors as Functional Disease Drivers. *Blood* **2020**, *136*(6), 698–714. [CrossRef] [PubMed]

[54] Fagnan, A.; Piqué-Borràs, M.-R.; Tauchmann, S.; Mercher, T.; Schwaller, J. Molecular Landscapes and Models of Acute Erythroleukemia. *HemaSphere* **2021**, *5*(5), e558. [CrossRef] [PubMed]

[55] Xiong, R.-J.; Tang, H.-X.; Yin, T.-T.; Pan, H.-Y.; Jin, R.-M. From Low Remission to Hope: The Efficacy of Targeted Therapies in NUP98-R Positive Pediatric Acute Myeloid Leukemia. *World J. Pediatr.* **2025**, *21*(3), 266–273. [CrossRef] [PubMed]

[56] Iyer, P. Pediatric AML: State of the Art and Future Directions. *Pediatr. Hematol. Oncol.* **2025**, *42*(2), 126–145. [CrossRef] [PubMed]

[57] Huang, B.J.; Meyer, L.K.; Alonzo, T.A.; Wang, Y.-C.; Lamble, A.J.; Ries, R.E.; Wang, W.; Hirsch, B.; Raca, G.; Ma, X.; et al. Hematopoietic Stem Cell Transplantation Outcomes for High-Risk AML: A Report from the Children's Oncology Group. *J.*

Clin. Oncol. **2025**, *43*(17), 1961–1971. [CrossRef] [PubMed]

[58] Heikamp, E.B.; Henrich, J.A.; Perner, F.; Wong, E.M.; Hatton, C.; Wen, Y.; Barwe, S.P.; Gopalakrishnapillai, A.; Xu, H.; Uckelmann, H.J.; et al. The Menin-MLL1 Interaction Is a Molecular Dependency in NUP98-Rearranged AML. *Blood* **2022**, *139*(6), 894–906. [CrossRef] [PubMed]

[59] Rasouli, M.; Blair, H.; Troester, S.; Szoltysek, K.; Cameron, R.; Ashtiani, M.; Krippner-Heidenreich, A.; Grebien, F.; McGeehan, G.; Zwaan, C.M.; et al. The MLL-Menin Interaction Is a Therapeutic Vulnerability in NUP98-Rearranged AML. *HemaSphere* **2023**, *7*(8), e935. [CrossRef] [PubMed]

[60] Heuser, M.; Freeman, S.D.; Ossenkoppele, G.J.; Buccisano, F.; Hourigan, C.S.; Ngai, L.L.; Tettero, J.M.; Bachas, C.; Baer, C.; Béne, M.-C.; et al. 2021 Update on MRD in Acute Myeloid Leukemia: A Consensus Document from the European LeukemiaNet MRD Working Party. *Blood* **2021**, *138*(26), 2753–2767. [CrossRef] [PubMed]

[61] Loken, M.R.; Alonzo, T.A.; Pardo, L.; Gerbing, R.B.; Raimondi, S.C.; Hirsch, B.A.; Ho, P.A.; Franklin, J.; Cooper, T.M.; Gamis, A.S.; et al. Residual Disease Detected by Multidimensional Flow Cytometry Signifies High Relapse Risk in Patients with de Novo Acute Myeloid Leukemia: A Report from the Children's Oncology Group. *Blood* **2012**, *120*(8), 1581–1588. [CrossRef] [PubMed]

Disclaimer/Publisher's Note: The views expressed in this article are those of the author(s) and do not necessarily reflect the views of the publisher or editors. The publisher and editors assume no responsibility for any injury or damage resulting from the use of information contained herein.